

University of Louisville

## ThinkIR: The University of Louisville's Institutional Repository

---

Electronic Theses and Dissertations

---

8-2010

### Ridge preservation comparing the clinical and histologic healing of a mineralized cortical vs. mineralized cancellous allograft with an acellular dermal matrix barrier membrane.

Marquez J. Sams  
*University of Louisville*

Follow this and additional works at: <https://ir.library.louisville.edu/etd>

---

#### Recommended Citation

Sams, Marquez J., "Ridge preservation comparing the clinical and histologic healing of a mineralized cortical vs. mineralized cancellous allograft with an acellular dermal matrix barrier membrane." (2010). *Electronic Theses and Dissertations*. Paper 1258.  
<https://doi.org/10.18297/etd/1258>

This Master's Thesis is brought to you for free and open access by ThinkIR: The University of Louisville's Institutional Repository. It has been accepted for inclusion in Electronic Theses and Dissertations by an authorized administrator of ThinkIR: The University of Louisville's Institutional Repository. This title appears here courtesy of the author, who has retained all other copyrights. For more information, please contact [thinkir@louisville.edu](mailto:thinkir@louisville.edu).

**RIDGE PRESERVATION COMPARING THE CLINICAL AND HISTOLOGIC  
HEALING OF A MINERALIZED CORTICAL VS. MINERALIZED  
CANCELLOUS ALLOGRAFT WITH AN ACELLULAR DERMAL MATRIX  
BARRIER MEMBRANE**

By

Marquez J. Sams  
DMD, University of Louisville, 2006

A Thesis  
Submitted to the Faculty of the  
Graduate School of the University of Louisville  
in Partial Fulfillment of the Requirements  
for the Degree of

Master of Science

Program in Oral Biology  
School of Dentistry  
University of Louisville  
Louisville, Kentucky

August 2010



**RIDGE PRESERVATION COMPARING THE CLINICAL AND HISTOLOGIC  
HEALING OF A MINERALIZED CORTICAL VS. MINERALIZED  
CANCELLOUS ALLOGRAFT WITH AN ACELLULAR DERMAL MATRIX  
BARRIER MEMBRANE**

By

Marquez J. Sams  
DMD, University of Louisville, 2006

A Thesis Approved on

June 23, 2010

By the following Thesis Committee:

---

Thesis Director

---

---

## **DEDICATION**

This manuscript is dedicated to my parents for their love and support and to the pursuit of science. The love and support from my parents has been invaluable. It has made me a humble, hard working, caring, and skillful healthcare provider. Science has the ability to enlighten humanity; therefore my efforts go towards its pursuit.

## **ACKNOWLEDGEMENTS**

I would like to express my sincere gratitude to the following individuals:

Dr. Henry Greenwell, Program Director of Graduate Periodontics, for his invaluable guidance and mentoring in my training as a periodontist, his help in the preparation of this thesis and for the lifelong friend I have acquired.

Dr. Margaret Hill, Assistant Program Director, for her inspiration and commitment to excellence and her caring encouragement of all the residents.

Dr. Brian S. Shumway, Assistant Professor, thank you very much for all of your help. I appreciate all of your input into my thesis.

## ABSTRACT

# RIDGE PRESERVATION COMPARING THE CLINICAL AND HISTOLOGIC HEALING OF A MINERALIZED CORTICAL VS. MINERALIZED CANCELLOUS ALLOGRAFT WITH AN ACELLULAR DERMAL MATRIX BARRIER MEMBRANE

Marquez Sams, DMD

June 23rd, 2009

**Aim.** To compare two techniques of ridge preservation using a mineralized cancellous particulate allograft to a mineralized cortical particulate allograft plus an acellular dermal matrix barrier membrane using clinical and histologic data to assess the outcome.

**Methods.** Twelve positive controls received a intrasocket mineralized cortical particulate allograft (500-800  $\mu\text{m}$ ) while twelve test patients received an intrasocket mineralized cancellous particulate allograft (500 to 800  $\mu\text{m}$ ). All sites were covered with acellular dermal matrix barrier. Following tooth extraction, horizontal ridge dimensions were measured with a digital caliper and vertical ridge dimensions were measured from a stent. Each site was re-entered for implant placement at about 4 months. Prior to implant placement, a 2.7 X 6 mm trephine core was obtained and preserved in formalin for histologic analysis.

**Results.** The mean horizontal ridge width at the crest of the Cancellous group decreased from  $8.4 \pm 1.1$  mm to  $6.3 \pm 1.6$  mm for a mean loss of  $2.0 \pm 1.6$  mm ( $p < 0.05$ ) while the Cortical group decreased from  $8.6 \pm 2.0$  mm to  $6.7 \pm 2.3$  mm for a mean loss of  $1.9 \pm 1.4$  mm ( $p < 0.05$ ). There were no statistically significance differences between the two groups ( $p > 0.05$ ). The mean mid-buccal vertical change for the Cancellous group was gain of  $1.3 \pm 3.3$  mm ( $p > 0.05$ ) vs. a gain of  $2.5 \pm 3.2$  mm for the Cortical group ( $p > 0.05$ ). There were no statistically significant differences between groups for vertical change ( $p > 0.05$ ). Histologic analysis revealed that the Cancellous group had  $37 \pm 13\%$  vital bone,  $21 \pm 13\%$  non-vital bone,  $43 \pm 6\%$  trabecular space, while the Cortical group revealed  $19 \pm 10\%$  vital bone,  $38 \pm 11\%$  non-vital bone, and  $43 \pm 11\%$  trabecular space. There were statistically significant differences between groups for vital and novital bone but not for trabecular space ( $p > 0.05$ ).

**Conclusions.** Both treatments were effective in the preservation of horizontal and vertical ridge dimensions for future implant placement, however, the Cancellous group had more vital bone and less non-vital bone than the Cortical group.



## TABLE OF CONTENTS

	<b>PAGE</b>
ACKNOWLEDGEMENTS.....	iv
ABSTRACT.....	v
TABLE OF CONTENTS.....	vii
LIST OF TABLES.....	ix
LIST OF FIGURES .....	x
 CHAPTER	
I. LITERATURE REVIEW	
Animal Extraction Socket Healing Sequence .....	1
Lindhe Studies.....	2
Human Extraction Socket Healing Sequence .....	6
Alveolar Ridge Resorption following Tooth Extraction.....	8
Clinical Studies of Ridge Preservation .....	11
Histologic Evaluation of Ridge Preservation.....	19
Extraction Alone Studies .....	20
Allograft Studies .....	20
Xenograft Studies.....	22
Alloplast Studies .....	24
Summary of Histologic Findings.....	26
Summary of Literature Review.....	29

II. MATERIALS AND METHODS	
Study Design .....	34
Inclusion Criteria.....	35
Exclusion Criteria.....	36
Post-Surgical Exclusion .....	36
Pre-surgical Management.....	36
Surgical Treatment .....	37
Re-entry Surgery .....	38
Histology .....	38
Statistics.....	38
III. RESULTS .....	40
IV. DISCUSSION.....	50
V. CONCLUSIONS.....	53
REFERENCES .....	57
APPENDICES.....	64
CURRICULUM VITAE.....	70

## LIST OF TABLES

<b>TABLE</b>	<b>PAGE</b>
1. Animal extraction socket healing 31 days (Clafin 1936).....	3
2. Animal extraction socket healing 180 days (Cardaropoli et al. 2003).....	3
3. Human extraction socket healing 56 days (Araujo et al. 2005a) .....	4
4. Human Extraction Socket Healing over 100 Days .....	7
5. Events In Extraction Socket Healing .....	8
6. Extraction Alone Studies Showing Change Alone .....	10
7. Extraction Alone Studies Showing Ridge Dimensions.....	11
8. Ridge Preservation Studies Showing Change Alone .....	17
9. Ridge Preservation Studies Showing Ridge Dimensions.....	18
10. Ridge Preservation Studies Showing Graft Type.....	19
11. Comparison of Histologic Data on Extraction Alone Studies.....	26
12. Comparison of Histologic Data on Ridge Preservation Studies .....	27
13. Root Dimensions at the Cervix by Tooth Types .....	31
14. Horizontal Ridge Width at the Crest for U of L Studies .....	33
15. U of L Studies by Tooth Type.....	33
16. Clinical Indices for Cancellous and Cortical Sites.....	43
17. Horizontal Ridge Width for Cancellous and Cortical Sites .....	44
18. Vertical Ridge Height Changes for Cancellous and Cortical Sites .....	45
19. CEJ to Osseous Crest Changes.....	46
20. Histologic Data for Cancellous and Cortical Sites.....	47
21. Comparison of Histologic Data from U of L Ridge Preservation Studies .....	48
22. Comparison of Histologic Data from U of L Ridge Augmentation Studies .....	49

## LIST OF FIGURES

FIGURE	PAGE
1. Study Design.....	35
2. Cancellous Pre- and Post-op.....	54
3. Cortical Pre- and Post-op.....	55
4. Representative Histologic Sections.....	56

## **CHAPTER I**

### **LITERATURE REVIEW**

The increased use of dental endosseous implants has become a significant part of periodontal practice. This demand for dental implants requires clinicians to be proficient at ridge preservation at the time of extraction to maintain post-extraction ridge width. Ridge preservation provides a site that should be sufficient for future implant placement. The events following tooth extraction with or without a ridge preservation procedure has been studied in animals and humans.

#### **Animal Extraction Socket Healing Sequence**

The earliest animal studies of socket healing date back to the 1930's. Claflin (1936) provided data on the histologic healing of extraction sockets up to 31 days in dogs (Table 1). The result of the study was that clot formation began at day 1, followed by infiltration with osteoclasts at day 3, then bone formation around 5-7 days. Complete epithelialization over the clot occurred at 7-9 days and socket fill was completed by 31 days. However, the presence of osteoclasts at 31 days indicated that healing was not complete. Cardaropoli et al. (2003) stated that the histologic healing sequence in beagle dogs spans a period of 180 days (Table 2). Though both studies agreed on the initial

phase of socket healing, Cardaropoli expanded on the complete remodeling process. According to Claflin, by day 30, the socket was completely filled with bone but active bone changes were still taking place. This indicates that immature bone fills the healing socket. Cardaropoli stated that not until 90 days was the remodeling process from woven (immature) bone to lamellar (mature) bone completed. By day 180, the lamellar bone had undergone further remodeling and showed a slight decrease in mineralization due to the replacement of lamellar bone with bone marrow.

### **Lindhe Studies**

Araujo et al. (2005a) examined histologic socket healing in the dog model using 12 sites in 12 mongrel dogs over a period of 8 weeks (Table 3). At 1 week, coagulum filled the central third of the socket and the apical third presented newly formed woven bone adjacent to the alveolar bone proper. At 2 weeks, large amounts of woven bone were found in the apical and lateral portion of the socket. Densely packed osteoblasts lined the outer surface of the woven bone. By week 4, there was no evidence of alveolar bone proper. On the outer surface of the buccal and lingual plate a large number of osteoclasts were noted. Alteration of ridge dimension was significant by week 8. The buccal wall was 2 mm apical to the lingual wall and considerably thinner. Between the buccal and lingual walls a mixture of woven and lamellar bone occupied the area. It can be concluded from this study that bundle bone begins to disappear as early as 2 weeks post-extraction and the buccal wall is resorbed to greater extent than the lingual wall.

**Table 1****Animal Extraction Socket Healing 31 Days (Clafin 1936)**

<b>Time</b>	<b>Event</b>
Day 1	Blood clot formation
Day 3	Osteoclast appear at crest of bone and fibroblast emerge form socket walls
Day 5 to 7	First bone formation
Day 7 to 9	Epithelialization over clot completed
Day 11 to 15	New bone reaching the alveolar crest
Day 28 to 31	Socket filled with new bone, with osteoclasts still present

**Table 2****Animal Extraction Socket Healing 180 Days (Cardaropoli et al. 2003)**

<b>Time</b>	<b>Event</b>
Day 1	Blood clot formation comprised mostly of erythrocytes and platelets
Day 3	Lysis of erythrocytes and clot being replaced by vascularized tissue
Day 7	New blood vessel formation
Day 14	New bone formation on socket walls
Day 30	Socket filled with new bone
Day 90	Woven bone replaced by lamellar bone
Day 180	Some lamellar bone being replaced by bone marrow spaces

**Table 3****Animal Extraction Socket Healing 56 Days (Araujo et al. 2005a)**

<b>Time</b>	<b>Event</b>
Day 7 (1 week)	- internal portion of the socket occupied by coagulum - apical portion showed islands of newly formed woven bone adjacent to the bundle bone.
Day 14 (2 weeks)	- apical & lateral portions showed large amounts of newly formed woven bone - surface of the woven bone was lined with densely packed osteoblasts - primitive bone marrow.
Day 28 (4 weeks)	- at the crestal region, all bundle bone had been lost - crestal lamellar bone replaced with woven bone. - apical to the crestal region, a multitude of osteoclasts were observed on the outer surfaces of the buccal and lingual walls.
Day 56 (8 weeks)	- lingual wall wider than buccal wall - lingual wall positioned 2 mm coronal to buccal wall - zone of mineralized tissue which consist of a mixture of woven and lamellar bone had formed between the buccal and lingual walls traveling in an oblique direction.

Aside from studies that examined the socket healing with extraction alone, Araujo et al. (2005b) studied the effects of immediate implant placement on the dimensional alterations of the alveolar ridge in beagle dogs. They compared sites that received an immediate implant to contralateral sites that received extraction alone over a period of 3 months. Extraction alone sites had a significant decrease in both height and width of the ridge. More importantly, the placement of an immediate implant failed to prevent the remodeling that occurred in the socket walls. After 3 months of healing results were similar for both groups. This indicated that dimensional changes should be expected with immediate implant placement.

In a 6 month study, Araujo et al. (2009) examined 5 mongrel dogs with bilateral extraction performed, one side had a full-thickness flap elevated while the contralateral



side received a flapless technique. Results showed that there were marked alterations following extraction with or without flap elevation, especially in the coronal portion. The coronal third of the edentulous ridge resulted in a 35% reduction in horizontal ridge dimension. There were no significant differences between the two techniques.

Berglundh et al. (1994) studied the vascular supply around Branemark implants in beagle dogs. It was observed that the blood vessels of the peri-implant mucosa were terminal branches of larger vessels from the periosteum at the implant site. The peri-implant supracrestal connective tissue, in comparison to a tooth, was almost devoid of vascular supply. Carmagnola et al. (2000) examined the histologic healing around implants placed in sites previously grafted with mineralized cortical bovine xenograft (Bio-Oss). Sixteen surgical defects were created in 4 beagle dogs. The results were that osseointegration failed to occur at the implant surfaces and a well-defined connective tissue capsule was present between implant surfaces, in addition to a deep vertical bone defect frequently present along the lingual surface of the implant. Botticelli et al. (2004) examined the effects of three different surgically created defect configurations on bone healing around implants. They concluded that 4-wall defects completely resolved following implant placement. However, defects with a missing buccal plate had incomplete healing. Botticelli et al. (2005), in a follow-up study, examined the effects of implant surface, implant position and the presence of combined horizontal and vertical residual peri-implant defects on osseointegration in Labrador dogs. After 4 months of healing, regardless of whether the implant was placed in a submerged or non-submerged position, a substantial amount of bone fill and a high degree of osseointegration were noted around roughened implants compared to machined implants. The outcomes of this

study suggest that implant surface characteristics play an important role in the amount of bone fill and level of osseointegration.

### **Human Extraction Socket Healing Sequence**

The following three studies evaluated extraction socket healing sequence in humans. Amler (1960) studied socket healing histologically, in 75 human extraction sockets over a period of 50 days. Boyne (1966), in a study of 12 patients requiring extractions of all remaining maxillary teeth, examined the histological healing of one of the maxillary first premolar sockets over 23 days. Evian (1982) examined the histologic healing in 10 patients over a period of 16 weeks. Biopsies were taken at 4, 6, 8, 10, 12, and 16 weeks post- extraction. These three studies showed that the human healing sequence followed a similar pattern to the dog models and is summarized in Table 4 below.

**Table 4**

**Human Extraction Socket Healing over 100 Days**

<b>Time</b>	<b>Event</b>
Day 1	Blood clot formation
Day 2-3	Granulation tissue appears
Day 4	Contraction of the blood clot begins
Day 7-10	New bone formation
Day 14	1/3 socket filled
Day 20	Connective tissue replaces granulation tissue
Day 38	2/3 socket filled
Day 100	Radiopacity of socket was identical to surrounding bone

The formation of a blood clot occurred at day 1 for both dogs and humans in the healing sequence (Claflin 1936, Amler 1960). The following events were slightly different in humans and animals with regard to time. New bone formation was seen around day 5 in dogs and along the lateral aspect of the socket by day 11 (Claflin 1936) but, in humans, new bone formation was not detected until day 7-10 (Amler 1960). Extraction sockets were completely filled with new bone around day 30 in dogs (Claflin 1936). In contrast, Amler noted that only 2/3 of the socket was filled at day 38 in humans, and Boyne (1966) reported that only 1/3 of the socket was filled by day 14 in humans. Mature, lamellar bone was seen in dogs at day 90 (Cardaropoli et al. 2003), and this was not evident until day 100 in humans (Amler 1960). Table 5 compares the socket healing sequence for the dog and human models.

**Table 5****Events In Extraction Socket Healing**

<b>Event</b>	<b>Time</b>	<b>Species</b>	<b>Study</b>
Blood Clot Formation	0 to 3 days	Dog	Clafin (1936)
	0 to 1 day	Human	Amler et al. (1960)
Fibroblast Proliferation	3 days	Dog	Clafin (1936)
	2 to 35 days	Human	Amler et al. (1960)
Osteoclast activity	3 to 31 days	Dog	Clafin (1936)
Osteoblast activity	5 to 31 days	Dog	Clafin (1936)
	7 days	Human	Amler et al. (1960)
	10 days	Human	Boyne (1966)
	28 days	Human	Evian et al. (1982)
First evidence of new bone	5 days	Dog	Clafin (1936)
	7-10 days	Human	Amler (1960)
Complete socket fill	30 days	Dogs	Clafin (1936)
1/3 socket fill	14 days	Human	Boyne (1966)
2/3 socket fill	38 days	Human	Amler (1960)
Mature bone present	90 days	Dog	Cardaropoli et al. (2003)
	100 days	Human	Amler (1960)

**Alveolar Ridge Resorption Following Tooth Extraction**

Many studies have examined the early loss of alveolar bone volume related to tooth extraction. This loss of alveolar ridge width and height can complicate the placement of endosseous dental implants where an adequate amount of bone is needed to encompass the implant. Ridge position can have a significant effect on implant placement, esthetics, and the subsequent occlusal relationship of the restored implant. The residual ridge

position is centered compared to the original edentulous ridge, or shifts toward the lingual. Most studies report that most of the ridge resorption occurs on the buccal aspect, resulting in a shift of the center of the ridge toward the palatal/lingual, (Lekovic et al. 1997, Lekovic et al. 1998, Iasella et al. 2003). Pietrokovski and Massler (1967) evaluated 149 dental casts with one tooth missing. Their results revealed that the buccal aspect of the alveolar ridge resorbs more than the lingual aspect independent of maxillary or mandibular arch location. The amount of facial resorption varied considerably between individual studies. Yilmaz et al. (1998) evaluated 5 patients (10 sites) with a single maxillary incisor extraction over a 12 month period and discovered a 17% decrease in ridge width. Schropp et al. (2003) found that most (2/3) resorption occurred in the first 3 months when evaluating study casts from 46 patients with a single premolar or molar extraction over a 12 month period. The amount of buccal-lingual ridge resorption after tooth extraction has been reported as 17-60% with the ridge height decreasing by 1 mm, (Lekovic et al. 1997, Lekovic et al. 1998, Yilmaz et al. 1998, Camargo et al. 2000, Schropp et al. 2003, Iasella et al. 2003). These changes in ridge dimension must be taken into account whenever future dental implant placement might be a potential treatment option. The greatest amount of bone loss occurs within the first 2 years after tooth removal (Ashman 2000). Loss of alveolar ridge width and height can complicate placement of an endosseous dental implant since there must be adequate bone to completely surround the dental implant. Whether the residual ridge position is centered compared to the original edentulous ridge, or it has shifted toward the lingual, is an important consideration. Barone et al. (2008) evaluated 40 patients (40 sites) in a non-molar extraction study that was followed for 7 months. He noted a decrease of 41.7% in

ridge width. The amount of buccal-lingual ridge resorption after tooth extraction has been reported as 17-63% with the ridge height decreasing by 1 mm (Lekovic et al. 1997, Lekovic et al. 1998, Yilmaz et al. 1998, Camargo et al. 2000, Schropp et al. 2003, Iasella et al. 2003, Barone et al. 2008). Data from these studies indicated that change in ridge width following tooth extraction varied substantially. Table 6 consists of studies that examined the mean change in the horizontal and vertical ridge dimensions following tooth extraction alone. These resorptive changes in ridge dimension may preclude future implant placement, or require additional surgical treatment to allow placement of functional, esthetic implants if ridge preservation is not performed at the time of extraction. Table 7 reports the ridge dimensions for the studies and percent change in ridge width.

**Table 6**

**Extraction Alone Studies Showing Change Alone**

<b>Extraction Alone Studies</b>				
<b>Study</b>	<b>Reentry Time (months)</b>	<b>Mean Horizontal Change mm</b>	<b>Percent Horizontal Change</b>	<b>Mean Vertical Change mm</b>
Lekovic et al. 1997	6	-4.43 ± 0.52	-62.9%	-0.88 ± 0.26
Lekovic et al. 1998	6	-4.59 ± 0.23	-61.3%	-1.50 ± 0.21
Yilmaz et al. 1998*	12	-0.75 ± 0.59	-17.0%	-1.35 ± 1.05
Camargo et al. 2000	6	-3.06 ± 2.41	-40.8%	-1.00 ± 2.25
Iasella et al. 2002	4-6	-2.63 ± 2.29	-28.6%	-0.90 ± 1.60
Schropp et al. 2003*	12	-6.1 ± 3.00	-50.8%	-0.20 ± 1.60
Barone et al. 2008	7	-4.5 ± 0.8	-41.7%	-3.60 ± 1.50
<b>Mean</b>	<b>7.6 ± 3.2</b>	<b>-3.7 ± 1.7</b>	<b>-43 ± 17</b>	<b>-1.2 ± 1.1</b>

\* = measured from study casts

**Table 7****Extraction Alone Studies Showing Ridge Dimensions**

<b>Study</b>	<b>Reentry Time (months)</b>	<b>Mean Initial Horiz</b>	<b>Mean Fin Horiz</b>	<b>Mean Horiz Change</b>	<b>% change</b>
Lekovic et al. 1997	6	7.0	2.6	-4.4	-63
Lekovic et al. 1998	6	7.5	2.9	-4.6	-61
Yilmaz et al. 1998*	12	4.7	3.9	-0.8	-17
Camargo et al. 2000	6	7.5	4.4	-3.1	-41
Iasella et al. 2002	4-6	9.1	6.4	-2.6	-29
Schropp et al. 2003*	12	12.0	5.9	-6.1	-51
Barone et al. 2008	7	10.8	6.3	-4.5	-42
<b>Mean</b>	<b>7.6 ± 3.2</b>	<b>8.4 ± 2.5</b>	<b>4.6 ± 1.6</b>	<b>-3.7 ± 1.7</b>	<b>-43 ± 17</b>

\* measured from study casts

**Clinical Studies of Ridge Preservation**

The primary goal of ridge preservation is minimizing loss of alveolar ridge dimension following an extraction. It has been documented that without this procedure substantial ridge resorption is likely to occur. Ashman (2000) noted that when an extraction takes place and ridge preservation is not utilized the site of extraction could lose 40% to 60% of bone dimension within 2 to 3 years and subsequent loss of 0.25% to 0.5% annually. Iasella (2003) reported as much as 4 mm loss of ridge width in extraction alone sites within 4 to 6 months.

Using an atraumatic tooth extraction technique plays a crucial role in preserving osseous walls, thereby improving the chances of osseous graft success. Garg (2001) discussed 5 steps he considered necessary for an atraumatic extraction: 1) do not reflect the interdental papilla, especially in the esthetic zone; 2) focus on the actual process of

tooth removal; 3) use elevators and forceps properly to reduce bony involvement and preserve bone contours; 4) section the tooth to help prevent bone loss; and 5) remove any soft tissue fragments or pathology. Horowitz (2005) added that use of a periosteal elevator is an important adjunct to atraumatic extractions. He stated that using periosteal elevators to sever the periodontal ligament fibers allows the extraction to be performed with significantly less trauma. The greater the number of bony walls present following extraction, the more likely the osseous graft will be successful.

Comparison studies have shown that intrasocket ridge preservation prevents most, but not all ridge resorption (Tables 8-10). Several ridge preservation studies have used barrier membranes in attempt to improve quality and quantity of bone fill in extraction sites. Both resorbable and non-resorbable barrier membranes have been used; some studies used membranes alone, others used membranes in conjunction with intrasocket grafting materials. Lekovic et al. (1997) compared extraction alone to use of a non-resorbable barrier membrane alone (Gore-Tex®) and Lekovic et al. (1998) compared extraction alone to use of a resorbable barrier membrane alone (Resolut®). In both studies, only non-molar teeth were included. The teeth were atraumatically extracted, the membrane was placed and primary closure was obtained. Reentry was performed 6-months post-extraction. The results showed that both the non-resorbable (Gore-Tex®) and resorbable (Resolut®) barrier membranes provided comparable results. There was mean vertical resorption of 0.35 mm and a mean horizontal resorption of 1.53 mm (20%). Results from Lekovic et al. (1997, 1998) reveal that the mean horizontal bone loss in the non-resorbable group (Gore-Tex®) was 1.73 mm, which was greater than the mean of 1.32 mm found in the resorbable membrane (Resolut®) group. The extraction alone



control group lost a mean of 4.5 mm. The non-resorbable membrane sites had a mean reduction of 3.70 mm of horizontal width (2.5 fold) when compared to sites treated with extraction alone while the resorbable membrane sites had a mean reduction of 3.27 mm of having width loss (3.5 fold). These two studies show that there is not much difference between the use of a resorbable vs. a non-resorbable membrane for ridge preservation. Membrane use did, however, greatly decrease the amount of horizontal and vertical bone resorption when compared to extraction alone. Fotek et al. (2009) extracted 18 non-molar teeth and grafted the socket with a mineralized bone allograft (Puros). In this 4-month study, 9 sockets were covered with a acellular dermal matrix (ADM) and the other 9 with polytetrafluoroethylene (PTFE) membrane. In the ADM group, there was 27.89% vital bone, 13.93% non-vital bone, and 59.19% trabecular space. There was 32.63% vital bone, 14.73% non-vital bone, and 52.64% trabecular space in the PTFE group. There appears to be no difference in the utilization of ADM or PTFE as a barrier in terms of histologic evidence. Camargo et al. (2000), in a 32 site ridge preservation study of nonmolar teeth with 6-month re-entry compared the use of bioactive glass (BioGran®) and calcium sulfate (Capset®) to extraction alone. The mixture of bioactive glass and calcium sulfate resulted in a mean loss of ridge width of 3.48 mm. The extraction alone resulted in a mean loss of ridge width of 3.06 mm which was less than the grafted sites. The extraction alone group showed a greater loss in ridge height (1.0 mm) over 6 months than the experimental group (0.4 mm). The results of the study concluded that the use of bioactive glass with calcium sulfate in preserving ridge width is not as effective as other techniques using traditional membrane barriers. Iasella et al. (2003) in a 4 to 6-month reentry study used 24 nonmolar sites and compared the use of freeze-dried bone allograft

(FDBA) with a resorable membrane (Biomend Extend®) to extraction alone. After four to six months of healing, the sites grafted with FDBA gained 1.3 mm in ridge height and lost only 1.2 mm in ridge width, in comparison to the extraction alone group, which had twice the amount of ridge width loss (2.6 mm), and 0.9 mm of ridge height loss.

Barone et al. (2008), compared corticocancellous porcine bone (MP3®) plus a collagen membrane (Evolution®) to extraction alone in 40 non-molar sockets with a 7 month re-entry. He reported that the corticocancellous porcine bone and collagen membrane group had a mean loss of ridge width and height of 2.0 mm and 0.7 mm, respectively. For the extraction alone group, he reported a mean loss of ridge width and height of 4.3 mm and 3.6 mm, respectively. In a 10 patient case series, Cardaropoli (2008) also studied corticocancellous porcine bone and a collagen membrane over 4 months. He reported a mean loss of 1.8 mm in ridge width after 4 months.

In addition to the extraction alone comparison studies, others have evaluated the effects of various graft materials used to preserve ridge dimensions. Nemcovsky and Serfaty (1996), in a 12-month, 23-patient, 23-socket study using non-resorbable hydroxyapatite (HA) crystals, showed a loss of ridge width of 0.6 mm and a loss of ridge height of 1.4 mm over 1 year. Simon et al. (2000) in a 4-month reentry study using particulate demineralized freeze-dried bone allograft (DFDBA) as an intrasocket and a buccal overlay graft along with a barrier membrane (Resolut XT®), reported an initial ridge width of  $6.2 \pm 0.2$  mm increasing to  $7.3 \pm 0.2$  mm for a gain of 1.1 mm. Zubillaga et al. (2003), in a 10-patient, 11-socket study compared the use of demineralized bone matrix paste (Regenafil®) and a resorbable barrier membrane (Resolut®) with or without fixation at four months. They reported that the mean change in ridge dimensions was a

loss of 1.8 mm width, and a gain of 1 mm height. Vance et al. (2004), in a 4-month nonmolar reentry study using 24 extraction sockets compared the use of anorganic bovine bone matrix (BioOss®) with a membrane to DFDBA plus mixture of calcium sulfate and carboxymethylcellulose (CalMatrix®). They demonstrated that both groups had a mean loss of 0.5 mm ridge width. The BioOss® group showed a gain in mean ridge height of 0.7 mm, while the CalMatrix® group showed a mean loss of 0.3 mm. Adams et al. (2005) compared two different ridge preservation techniques in nonmolar sites in a 4 month re-entry study. An intrasocket cortical FDBA graft alone was compared to an intrasocket plus a buccal overlay (extrasocket) cortical FDBA graft. The intrasocket alone group had a mean ridge width loss of 2 mm and no change in ridge height. In contrast, the overlay group showed a mean ridge width loss of 1.4 mm and a gain of 2.2 mm of ridge height. Brkovic et al. (2008) in a single case report evaluated an alveolar preservation technique involving placement of a cone of beta-tri-calcium phosphate (TCP) combined with type I collagen (RTR Cone®) without the use of a barrier or flap. Nine months after tooth extraction, they reported no reduction in ridge height and no change in ridge width. Neiva et al. (2008) in a 24 patient study over 4 months compared an anorganic bovine-derived hydroxyapatite matrix combined with a synthetic P-15 Putty (PepGen P-15 Putty®) and a bioabsorbable collagen wound dressing (CollaPlug®) to a bioabsorbable wound dressing alone. Neiva reported a loss of 1.31 mm in ridge width and a gain of 0.15 mm in ridge height for the Putty P15 group. For the bioabsorbable collagen wound dressing alone, a loss of 1.43 mm for ridge width and a loss of 0.56 mm in ridge height was reported (Tables 8,9).

As the previous studies have indicated, even with the use of ridge preservation techniques to decrease the extent of bone resorption after an extraction, some loss of vertical and horizontal dimensions is likely to occur. However, without ridge preservation being performed after an extraction, the risk of decreased horizontal dimension significantly increases. Over a 4-6 month period, a 30-60% change (2.7 to 6.1 mm) in horizontal dimension can be anticipated (Lekovic et al. 1997, Lekovic et al. 1998, Iasella et al. 2003, Schropp et al. 2003, Barone et al. 2008), ultimately, complicating and/or delaying implant placement

**Table 8**

**Ridge Preservation Studies Showing Change Alone**

Study	Reentry Time months	Treatment	Mean Horizontal Change mm	Percent Horizontal Change	Mean Vertical Change mm
Nemcovsky & Serfaty 1996	12	Nonresorbable HA crystals	-0.6 ± 0.66	N/A‡	-1.4 ± 0.50
Lekovic et al. 1997	6	ePTFE	-1.7 ± 0.56	-23.3%	-0.3 ± 0.26
Lekovic et al. 1998	6	Resolut	-1.3 ± 0.21	-17.6%	-0.4 ± 0.20
Yilmaz et al. 1998	6	PerioGlas cones	+0.2 ± 0.52	+3.6%	-0.1 ± 0.87
Camargo et al. 2000	6	BioGran Capset	-3.5 ± 2.68	-44.3%	-0.4 ± 3.18
Simon et al. 2000	4	DFDBA/ Resolut XT®	+1.1 ± NG*	+18%	-1.4 ± NG*
Iasella et al. 2003	4	FDBA/ BioMend	-1.2 ± 0.93	-13.0%	+1.3 ± 2.00
Zubillaga et al. 2003	4	Regenafil	-1.8 ± NG*	-16.8%	+1.0 ± NG*
Vance et al. 2004	4	BioOss/ BioGide	-0.5 ± 0.8	-5.2%	+0.7 ± 0.4
Vance et al. 2004	4	CalMatrix/ Capset	-0.5 ± 0.8	-5.6%	-0.3 ± 0.6
Barone et al. 2008	7	xenograft, collagen mem	-2.0 ± 0.9	-23.6%	-0.7 ± 1.4
Brkovic et al. 2008	9	B-TCP + coll	0.0 ± 0.0	0.0%	0.0
Cardaropoli et al. 08	4	xenograft/coll membrane	-1.9 ± 1.7	-16.1%	NA
Neiva et al. 2008	4	P15/Collaplug	-1.3 ± 0.9	NA	+0.2 ± 1.8
Neiva et al. 2008	4	Collaplug	-1.4 ± 1.1	NA	-0.6 ± 1.0
Fotek et al. 2009	4	FDBA/ADM	-0.44	NA	-1.11
Fotek et al. 2009	4	FDBA/PTFE	-0.39	NA	-0.25
<b>Mean ± sd</b>			<b>-2.0 ± 1.1</b>	<b>-12 ± 16</b>	<b>-0.1 ± 0.8</b>

\* NG = not given in article

‡ = no baseline measurements reported, unable to determine percentage

**Table 9****Ridge Preservation Studies Showing Ridge Dimensions**

<b>Study</b>	<b>Reentry Time (months)</b>	<b>Mean Initial Horiz</b>	<b>Mean Fin Horiz</b>	<b>Mean Horiz Change</b>	<b>% change</b>
Nemcovsky & Serfaty 1996	12			-0.6	
Lekovic et al. 1997	6	7.3	5.6	-1.7	-23
Lekovic et al. 1998	6	7.4	6.1	-1.3	-18
Yilmaz et al. 1998	6	5.5	5.7	+0.2	+4
Camargo et al. 2000	6	7.9	4.4	-3.5	-44
Simon et al. 2000	4	6.2	7.3	+1.1	+18
Iasella et al. 2003	4	9.2	8.0	-1.2	-13
Zubillaga et al. 2003	4	10.7	8.9	-1.8	-17
Vance et al. 2004	4	8.9	8.4	-0.5	-6
Vance et al. 2004	4	9.7	9.2	-0.5	-5
Barone et al. 2008	7	10.6	8.1	-2.5	-24
Brkovic et al. 2008	9	12.0	12.0	0	0
Cardaropoli et al. 08	4	11.8	9.9	-1.9	-16
Neiva et al. 2008	4			-1.3	
Neiva et al. 2008	4			-1.4	
Fotek et al. 2009	4			-0.4	
Fotek et al. 2009	4			-0.3	
<b>Mean</b>	<b>5.8 ± 2.6</b>	<b>8.9 ± 2.1</b>	<b>7.8 ± 2.1</b>	<b>-2.0 ± 1.1</b>	<b>-12 ± 16</b>

**Table 10****Ridge Preservation Studies Showing Graft Type**

<b>Graft Type</b>	<b># studies</b>	<b>Initial Horiz</b>	<b>Final Horiz</b>	<b>Change Horiz</b>	<b>% Change</b>	<b>Change Vertical</b>
Allograft	6	8.8 ± 1.9	8.1 ± 0.7	-0.5 ± 1.0	-5 ± 15	0.1 ± 1.0
Xenograft	4	10.7 ± 1.1	9.1 ± 0.9	-1.6 ± 0.9	-15 ± 9	0.1 ± 0.7
Alloplast	4	8.5 ± 3.3	7.4 ± 4.1	-1.0 ± 1.7	-14 ± 27	-0.5 ± 0.6
Membrane alone	2	7.4 ± 0.1	5.8 ± 0.4	-1.5 ± 0.3	-20 ± 4	-0.4 ± 0.1
Filler				-1.4		0.4 ± 1.3

Horiz = Horizontal

**Histologic Evaluation of Ridge Preservation**

The ideal bone grafting material will rapidly turnover, produce vital bone that fills the socket and, at the same time, maintain ridge dimensions. Histologic evaluation of bone quality is an important factor in the determining the appropriate material to use for a ridge preservation procedure. Bone quality also plays an important role in the process of implant placement. A bone quality index has been described by Lekholm and Zarb (1985) which includes Type I bone being homogenous compact bone, Type II being a thick layer of compact bone surrounding a core of dense trabecular bone, Type III being a thin layer of cortical bone surrounding dense trabecular bone of favorable strength and Type IV being a thin layer of cortical bone surrounding a low-density trabecular bone. Type I

bone is preferred for implant placement since it has the highest density of cortical bone and Type IV is the least preferred due to its very low density.

### **Extraction Alone Studies**

The percentage of vital bone relative to trabecular space at 4-8 months, in an extraction socket, ranges from 26-54% while there was 46-67% trabecular space (Iasella et al. 2003, Froum et al. 2002, Serino et al. 2003, Barone et al. 2008, Table 11). Cardaropoli et al. (2003), in a 6 month canine study, reported only 15% vital bone and 85% trabecular space over 6 months. It has been suggested that the large amount of trabecular space is due to the lack of load.

### **Allograft Studies**

Mineralized particulate freeze-dried bone allograft (FDBA) and demineralized particulate freeze-dried bone allograft (DFDBA) are the primary two forms of allografts available commercially. FDBA provides an osteoconductive scaffold while DFDBA may provide osteoinductive proteins in addition to the osteoconductive scaffold (Mellonig et al. 1981, Mellonig 1991). The osteoinductive properties of DFDBA have been attributed to the presence of bone morphogenetic proteins (BMPs). Urist et al. (1965) identified BMPs, which were recognized to have osteoinductive potential. Urist et al. (1971) isolated BMPs from human cortical bone. BMPs were placed in ectopic sites in athymic mice, which then initiated bone formation. The demineralization process of allograft preparation releases BMP and allows osteoinduction to occur. Age and health status are



factors that could affect osteoinductive potential. Commercial DFDBA from different bone banks exhibited wide variation in osteoinductive capabilities (Schwartz et al. 1996, 1998, 2000). There was an age-dependent decrease in new bone induction for donors over the age of 50.

Studies of demineralized freeze-dried bone allograft (DFDBA) used in ridge preservation procedures have reported conflicting results in regard to bone turnover. Histologic evaluations have shown a significant amount of non-vital DFDBA particles still present in core samples (Smukler et al. 1999, Froum et al. 2002). Becker et al. (1998) reported that several histologic samples showed DFDBA particles were encapsulated in dense connective tissue with no evidence of either osteoblastic or osteoclastic activity. This finding suggests that DFDBA may interfere with normal socket healing ultimately affecting bone to implant contact (Becker et al. 1994, 1996, 1998). In contrast, other studies have found that DFDBA particles fully resorb in some cases leaving only vital bone (Vance et al. 2004). In many cases, DFDBA has residual graft particles surrounded by intimately apposed woven and lamellar bone with distinct cement lines and a lack of fibrous encapsulation. Osteoblasts lined endosteal spaces and the new bone marrow exhibited a mild degree of fibrosis without signs of an inflammatory reaction (Brugnami et al. 1996, 1999, Smukler et al. 1999). Vance et al. (2004) examined 12 sockets grafted with a combination of DFDBA and an alloplastic putty consisting of calcium sulfate and carboxymethylcellulose (CalMatrix®) over 4 months. Histologic analysis showed 61% vital bone, 3% non-vital bone, and 36% trabecular space. In previous studies, the percentage of vital bone present after utilizing DFDBA in ridge preservation ranged from 35 to 60% while only about 3-14% non-vital

residual graft particles were present (Table 12). It must be noted that the failure to use an occlusive barrier membrane may be the cause of more residual graft particles and fibrous encapsulation in graft sites (Becker et al. 1996, 1998).

Freeze-dried bone allograft (FDBA), for a ridge preservation procedure showed a histologic result of 28% vital bone, 37% non-vital bone and 35% trabecular space over 4-6 months (Iasella et al. 2003). The residual FDBA particles were often surrounded by vital woven or lamellar bone, or were encapsulated in fibrous connective tissue. The residual graft material was higher than the amount with DFDBA, which may be due to the shorter healing period of 4-6 months vs. up to 48 months for DFDBA. Wang et al. (2008) grafted five patients with solvent preserved mineralized particulate cancellous allograft (Puros®). After 5 to 6 months they reported 69% vital bone, 3.8% residual graft particles and 27% trabecular space. Comparison of the two grafting materials is difficult since the healing periods were different for each of the studies.

### **Xenograft Studies**

Xenografts, mostly anorganic bovine bone, have also been utilized in ridge preservation procedures with similar results to allografts (Table 12). The particles showed evidence of osteoconductivity based on osseous ingrowth and close integration with newly formed bone (Artzi et al. 1998, 2001, Froum et al. 2004, Table 12). Vance et al. (2004) showed that BioOss® had 26% vital bone with 16% non-vital bone and 58% trabecular space after 4 months of healing. Zitzmann et al. (1997, 2001) reported similar results, in a 6-month study of 6 sockets grafted with BioOss®, 27% vital bone, 30% non-

vital bone, and 43% trabecular space. Neiva et al. (2008), in a 24 patient study, compared a putty-form anorganic bovine-derived hydroxyapatite matrix combined with a synthetic cell-binding peptide P-15 (Putty P15) to a bioabsorbable collagen membrane to a bioabsorbable collagen dressing alone. He reported that the Putty P15 had 29.92% vital bone, 65.25% bone marrow and 6.25% non-viable bone. The bioabsorbable group was reported to have 36.54% vital bone and 62.67% bone marrow. Nevins et al. (2009), in a 4 to 6 month study, grafted 8 socket with a mineralized collagen substitute (Bio-Oss Collagen) combined with platelet-derived growth factor-BB without a barrier. All treatment sites achieved adequate bone for the placement of standard size implants. There was 20% vital bone, 13.3% non-vital bone, and 66% trabecular space after 4 to 6 months of healing. Artzi et al. (2000) and Froum et al. (2004) found that xenografts produced a greater percentage of vital bone. Artzi et al. (2000), in a 9-month study, grafted 15 sockets in 15 patients using BioOss® and reported 46% vital bone, 31% non-vital bone, and 23% trabecular space. Froum et al. (2004), in a 6 to 8 month study, grafted 8 sockets with a nonresorbable anorganic bovine bone substitute (OsteoGraf R/N-300®), 4 of which were combined with an ePTFE barrier, and the other 4 with Alloderm® (ADM) as a barrier. In the OsteoGraf/ePTFE group, there was 18% vital bone, 21% non-vital bone, and 61% trabecular space. The OsteoGraf/ADM® group resulted in 42% vital bone, 13% non-vital bone, and 45% trabecular space. The two groups exhibited different amounts of vital bone, which was attributed to the choice of barrier material. The vascular channels in the Alloderm may have provided better revascularization compared to the ePTFE barrier. Araujo et al. (2008) grafted one quadrant of fresh extractions sockets in mongrel dogs with Bio-Oss Collagen® the other

side was not grafted. After 3 months of healing, sites grafted with Bio-Oss Collagen® had 27% bone marrow, 58% vital bone, and 12% residual graft particles. The high percentage of vital bone was attributed to the incorporation of collagen into the BioOss®. In a 40 patient study, Barone et al. (2008) compared grafting 20 sockets with OsteoBiol MP3® and a collagen membrane (OsteoBiol Evolution®) to extraction alone over 7 months. In the OsteoBiol MP3/Evolution group, they reported 36% vital bone, 29% non-vital bone, and 37% connective tissue. The percentage of vital bone present in sites grafted with xenografts appears to be strongly associated with the length of the healing period.

### **Alloplast Studies**

Alloplastic materials such as bioactive glass, hydroxyapatite (HA) and calcium sulfate have been shown to produce vital bone formation from 25 to 60% (MacNeill et al. 1999, Froum et al. 2002, 2004 Guarnieri et al. 2004, and Mangano et al. 2008). These materials are osteoconductive and have no osteoinductive properties. Gaurnieri et al. (2004), in a 3 month study, utilized medical grade calcium sulfate hemihydrate in 10 sockets and reported 58% vital bone and no residual graft particles in preserved sites. The sites were also devoid of any inflammatory cells and connective tissue. Calcium sulfate has a notably faster resorption time than xenografts and allografts. Hydroxyapatite, on the hand, has an extremely slow resorption rate as reported by Mangano et al. (2008) in a 20-year case report. Dense hydroxyapatite was used in post-extraction sites to maintain the alveolar height. Histologic analysis showed that vital bone represented 25.4% of the

graft area, trabecular space 41.3% and HA residual particles 38.1%. MacNeill et al. (1999) compared the histologic healing of 4 different alloplasts: hydroxyapatite (HA, OsteoGraf/P®), bioactive glass #1 (BioGran® 300-360  $\mu\text{m}$ ), bioactive glass #2 (PerioGlas® 90-710  $\mu\text{m}$ ), and calcium sulfate (Capset®) with autogenous bone, in osteotomy sites surgically created in the rabbit tibia over 28 days. All graft sites showed evidence of new bone formation at one month with the Capset® plus autogenous bone showing the greatest mean percentage of vital bone (58.8%) and PerioGlas® showing the least (40.4%), while the BioGran® and OsteoGraf/P® group both showed 41.8% vital bone. Froum et al. (2002) found similar results when treating 19 human sockets were with BioGran® over a 6-8 months period. Sockets treated with BioGran® resulted to 59% vital bone, 6% non-vital bone, and 35% trabecular space. Froum et al (2004) treated 8 sockets with absorbable HA (OsteoGraf R/LD®), 4 of which were combined with an ePTFE barrier, while the remaining 4 were treated with an Alloderm® (ADM) barrier. After 6-8 months of healing, the HA/ADM group showed 35% vital bone, 4% non-vital bone, and 62% trabecular space, while the HA/ePTFE group showed 28% vital bone, 12% non-vital bone, and 61% trabecular space (Table 12). Serino et al. (2003) treated 34 sockets, in a 6 month study, with a bioabsorbable polylactide/polyglycolic acid sponge (Fisiograft®). Histologic analysis resulted in 67% vital bone and 33% trabecular space. In a 3 month study, Crespi et al. (2009) evaluated 45 sockets, 15 grafted with magnesium-enriched hydroxyapatite (MHA), 15 grafted with calcium sulfate (CS), while the remaining 15 were non-grafted sites. The MHA group resulted in 40% vital bone, 20.2% non-vital bone, and 41.3% trabecular space. In the CS group there was 45% vital bone, 13.9% non-vital bone, and 41.5% trabecular space. The CS group had a greater

percentage of vital bone and less non-vital bone, indicating greater bone formation and faster resorption. In a single 9-month case report, Brkovic et al. (2008) evaluated beta-TCP with type I collagen (RTR Cone®, Septodont, Saint-Maur-des-Fosses, France) and reported 62.6% vital bone, 21.1% marrow and 16.3% residual B-TCP graft. This is the highest percentage of vital bone reported for the alloplasts.

### Summary of Histologic Findings

The percentage of vital and nonvital bone as well as trabecular space varies considerably, when analyzing the histologic findings of studies of ridge preservation procedures performed using a variety of grafting materials, including allografts (DFDBA, FDBA), xenografts (anorganic bovine bone mineral), or alloplasts (hydroxyapatite, calcium sulfate, and polylactide/polyglycolic acid sponge). The percentage of vital bone ranged from 1-67%, the percentage of non-vital bone ranged from 0-42%, and the percentage of trabecular space ranged from 33-85%.

**Table 11**

#### Comparison of Histologic Data on Extraction Alone studies

Author/Yr	Species	Healing Months	% Vital Bone	% Trabecular Space
Froum et al. 2002	Human	6-8	32.4	67.6
Iasella et al. 2003	Human	4-6	54.0	46.0
Serino et al. 2003	Human	6	44.0	56.0
Barone et al. 2008	Human	7	26	59.0
Crespi et al. 2009	Human	3	33.0	65.0
<b>Mean ± sd</b>		<b>6 ± 2</b>	<b>38 ± 11</b>	<b>56 ± 13</b>

**Table 12**

**Comparison of Histologic Data on Ridge Preservation studies**

<b>Author/Yr</b>	<b>Graft Material</b>	<b>Particle Size</b>	<b>Healing Months</b>	<b>% Vital Bone</b>	<b>% Non-Vital Bone</b>	<b>% Trabecular Space</b>
<b>Allografts</b>						
Froum et al. 2002	DFDBA	250 to 500 $\mu\text{m}$	6-8	34.7	13.5	51.8
Iasella et al. 2003	FDBA	500-1000 $\mu\text{m}$	4-6	30.1	34.7	35.2
Vance et al. 2004	DFDBA/putty (CalMatrix®)	500-1000 $\mu\text{m}$	4	61.0	3.0	36.0
Fotek et al. 2009	Canc Puros/ADM	250-1000 $\mu\text{m}$	4	28	14	58
Fotek et al. 2009	Canc Puros/PTFE	250-1000 $\mu\text{m}$	4	33	15	52
<b>Mean <math>\pm</math> sd</b>				<b>41 <math>\pm</math> 17</b>	<b>18 <math>\pm</math> 17</b>	<b>38 <math>\pm</math> 13</b>
<b>Xenografts</b>						
Artzi et al. 2000	BioOss®	250-1000 $\mu\text{m}$	9	46.3	30.8	42.6
Zitzmann et al. 2001	BioOss®	250-1000 $\mu\text{m}$	6	26.9	30.5	42.6
Froum et al. 2004	OsteoGraf R/N300 + ADM	250-420 $\mu\text{m}$	7	42.0	13.0	45.0
Froum et al. 2004	OsteoGraf R/N300 +ePTFE	250-420 $\mu\text{m}$	7	18.0	21.0	61.0
Vance et al. 2004	BioOss®	250-500 $\mu\text{m}$	4	26.0	16.0	54.0
Barone et al. 2008	OsteoBiol MP3 + OsteoBiol Evolution	600-1000 $\mu\text{m}$	7	35.5	29.2	36.6
Cardaropoli et al. 2008	OsteoBiol GenOs + OsteoBiol Evolution	250-1000 $\mu\text{m}$	4	NR	24.5	NR
Neiva et al. 2008	Putty P-15 + collaPlug	250-420 $\mu\text{m}$	4	29.9	6.3	65.3
<b>Mean</b>			<b>6 <math>\pm</math> 2</b>	<b>31 <math>\pm</math> 9</b>	<b>23 <math>\pm</math> 11</b>	<b>47 <math>\pm</math> 14</b>

<b>Alloplasts</b>						
Froum et al. 2002	Bioactive Glass (BioGran®)	300-355 $\mu\text{m}$	6-8	59.5	5.5	35.0
Froum et al. 2004	HA (OsteoGraf R/LD) + ADM	250-420 $\mu\text{m}$	4	35.0	4.0	62.0
Froum et al. 2004	HA (OsteoGraf R/LD) + ePTFE	250-420 $\mu\text{m}$	4	28.0	12.0	61.0
Luczyszyn et al. 2005	HA (Algipore®) + ADM	NA	6	1.0	42.0	57.0
Brkovic et al. 2008	B-TCP, Type 1 collagen	500-1000 $\mu\text{m}$	9	62.6	16.3	21.1
Mangano et al. 2008	dense HA	1 to 2 $\mu\text{m}$	240	25.4	38.1	41.3
Crespi et al. 2009	Magnesium HA		3	40	20	41
<b>Mean</b>			<b>7 <math>\pm</math> 2</b>	<b>36 <math>\pm</math> 21</b>	<b>20 <math>\pm</math> 15</b>	<b>46 <math>\pm</math> 15</b>
<b>Membrane Alone</b>						
Luczyszyn et al. 2005	ADM	NA	6	46.0	0.0	54.0
<b>Collagen Filler Material</b>						
Serino et al. 2003	Poly lactide/ Polyglycolic acid sponge (Fisiograft®)	NA	6	67.0	0.0	33.0
Neiva et al. 2008	Collaplug	NA	4	36.5	0.0	62.7
<b>Mean</b>				<b>52 <math>\pm</math> 21</b>	<b>0 <math>\pm</math> 0</b>	<b>48 <math>\pm</math> 21</b>

\*NR= not reported in article



## Summary of Literature Review

The events that occur following extraction alone have been studied in animal and human models. The healing sequence of an extraction socket begins with the formation of a blood clot around day 1, followed by neovascularization around day 3, and subsequent new bone formation starting at around 5-7 days (Clafin 1936, Cardaropoli et al. 2003, Amler 1960, Boyne 1966, Evian 1982). There are some slight differences in animals and humans in regards to healing. Complete socket fill was noted at day 30 in dogs (Clafin 1936), while only 2/3 of the socket was filled in humans at day 38 (Amler 1960). Mature, lamellar bone was seen as early as 90 days in dogs (Cardaropoli et al. 2003), but this was not present until day 100 in humans (Amler 1960).

The results from studies of the histologic healing of the extraction sockets have shown that without any type of ridge preservation procedure the percentage of vital bone present after 4-8 months of healing ranged from 33-54% with 34-67% of trabecular space (Iasella et al. 2003, Froum et al. 2002, Serino et al. 2003, Barone et al. 2008). Cardaropoli et al (2003) in the canine model reported only 15% vital bone and 85% trabecular space after 6 months of healing.

Histologic results vary within and between graft types. Studies using allografts (DFDBA, FDBA) for ridge preservation (Smukler et al. 1999, Froum et al. 2002, Vance et al. 2004, Iasella et al. 2003) have yielded variable results. Percentage of vital bone ranged from 30-61%, non-vital bone ranged from 3-35%, while percentage trabecular space ranged from 35-56%. Variations in the results may be attributable to the range in time of re-entry from 4 to 240 months. Ridge preservation studies using xenografts (BioOss®, OsteoGraf®) showed similar results to allografts with a range of 18-46% of

vital bone, 13-31% of non-vital bone, and 43-61% of trabecular space. The variation in results in studies using alloplasts (BioGran®, PerioGlas®, Algipore®, hydroxyapatite, calcium sulfate, Fisograft®, Collaplug®) differed significantly with re-entry times from 1 to 8 months. From these studies, a range of 1-67% vital bone, 0-42% non-vital bone, and 33-62.7% trabecular space were reported. Lastly, (Nevins et al. 2009), examined the use of a BioOss Collagen® and PDGF for ridge preservation and they reported 21% vital bone, 13% non-vital bone, and 66% trabecular space.

Loss of alveolar ridge width following tooth extraction is a common reported sequelae. This loss of alveolar ridge width can significantly complicate and delay the time of implant placement. All sockets lose horizontal width irrespective of their initial width. Thus sockets that are initially narrow, such as incisors, will end up still narrower following healing. Therefore the tooth type may be one of main variables in determining the feasibility of placement of a dental implant and may be predictive of the final outcome. Table 13 summarizes the root dimensions at the cervix as categorized by tooth types.

**Table 13****Root Dimensions at the Cervix by Tooth Types (Ash-Wheeler 6<sup>th</sup> Ed. 1984, Woelfel 1990)**

Tooth Types	Bucco-lingual/palatal dimensions mm		Mesio-distal dimensions mm	
	Ash-Wheeler	Woelfel	Ash-Wheeler	Woelfel
Mandibular incisors				
Central	5.3	5.4	3.5	3.5
Lateral	5.8	5.8	4.0	3.8
Maxillary incisors				
Central	6.0	6.4	7.0	6.4
Lateral	5.0	5.8	5.0	4.7
Mandibular & Maxillary canines	7.0	Mx: 7.6 Mn: 7.5	5.5	Mx: 5.6 Mn: 5.2
Mandibular 1 <sup>st</sup> premolars	6.5	7.0	5.0	4.8
Mandibular 2 <sup>nd</sup> premolars	7.0	7.3	5.0	5.0
Maxillary premolars (1 <sup>st</sup> & 2 <sup>nd</sup> )	8.0	1 <sup>st</sup> : 8.2 2 <sup>nd</sup> : 8.1	5.0	1 <sup>st</sup> : 4.8 2 <sup>nd</sup> : 4.7
Mandibular 1 <sup>st</sup> molars	9.0	10.7	9.0	7.9
Mandibular 2 <sup>nd</sup> molars	9.0	10.7	8.0	7.6
Mandibular 3 <sup>rd</sup> molars	9.0	10.4	7.5	7.2
Maxillary 1 <sup>st</sup> molars	10.0	9.0	8.0	9.2
Maxillary 2 <sup>nd</sup> molars	10.0	8.8	7.0	9.1
Maxillary 3 <sup>rd</sup> molars	9.5	8.9	6.5	9.2

Different tooth types possess different bucco-lingual/palatal and mesio-distal dimensions (Table 13). In general, incisors are the smallest, while molars are the widest in dimension. As a result, ridge preservation becomes increasingly critical for the smaller tooth types, especially mandibular incisors, since even a small amount of horizontal ridge resorption can be detrimental.

The main goal of ridge preservation is to minimize the loss of alveolar ridge dimension following extraction. As was evident from the extraction alone studies

reviewed (Lekovic et al. 1997, Lekovic et al. 1998, Yilmaz et al. 1998, Camargo et al. 2000, Iasella et al. 2002, Schropp et al. 2003), the change in ridge width following tooth extraction varies substantially, and this broad range (30-60%) may have a profound influence on the future tooth replacement options available.

Despite the use of a bone graft to preserve alveolar ridge dimensions, most studies have reported a net loss in horizontal and/or vertical ridge dimensions. However, Simon et al. (2000) in a 4-month reentry study using particulate DFDBA as an intrasocket and a buccal overlay graft along with a barrier membrane (Resolut XT®), reported a mean net gain of approximately 1.1 mm of ridge width.

The University of Louisville has studied ridge preservation since 2003 (Iasella, Vance, Adams, Siu, Witonsky). Since that time horizontal ridge width change has ranged from -0.5 to -2.0 mm with a mean of -1.1 mm. The percent change has ranged from -5 % to -21 % with a mean of -13 %. A small amount of ridge loss could be due to the small amount of time the flap was open, while a longer surgical procedure may lead to more bone loss (Table 14). Another factor in varying results is tooth type. According to the University of Louisville studies (Table 15), maxillary tooth types compared to the same mandibular tooth types had a greater percentage ridge width loss. Thus, results of a study could vary based on the distribution of teeth in the sample (Table 15).

**Table 14**

**Horizontal Ridge Width at the Crest for U of L Studies**

**Mean ± sd in mm**

	<b>Initial</b>	<b>Final</b>	<b>Change</b>	<b>% Change</b>
<b>Iasella 2003 FDBA</b>	9.2 ± 1.2	8.0 ± 1.4	-1.2 ± 0.9	-13
<b>Vance 2004 Calmatrix</b>	8.9 ± 1.8	8.4 ± 1.5	-0.5 ± 0.7	-6
<b>Vance 2004 BioGide/BioOss</b>	9.7 ± 1.1	9.2 ± 1.1	-0.5 ± 0.8	-5
<b>Adams 2005 Intra FDBA</b>	9.4 ± 1.2	7.4 ± 1.5	-2.0 ± 0.9*	-21
<b>Adams 2005 Overlay FDBA</b>	8.5 ± 1.0	7.1 ± 1.2	-1.4 ± 1.0*	-17
<b>Siu 2007 Flap</b>	8.5 ± 1.5	7.5 ± 1.5	-1.0 ± 1.1	-12
<b>Siu 2007 Flapless</b>	8.3 ± 1.3	7.0 ± 1.9	-1.3 ± 1.0	-16
<b>Witonsky 2009 BioCol</b>	8.6 ± 1.0	7.3 ± 1.0	-1.3 ± 0.9	-15
<b>Witonsky 2009 PTFE</b>	7.9 ± 1.5	6.8 ± 1.4	-1.1 ± 1.1	-14
<b>Sams 2010 Cortical</b>	8.6 ± 2.0	6.7 ± 2.3	-1.9 ± 1.4	-23
<b>Sams 2010 Cancellous</b>	8.4 ± 1.1	6.3 ± 1.6	-2.0 ± 1.6	-24
<b>Mean</b>	<b>8.7 ± 1.4</b>	<b>7.5 ± 1.7</b>	<b>-1.3 ± 1.2</b>	<b>-14 ± 14</b>

\* = p < 0.05 between initial and 4-month values

**Table 15**

**U of L Studies by Tooth Type**

**Mean ± sd in mm**

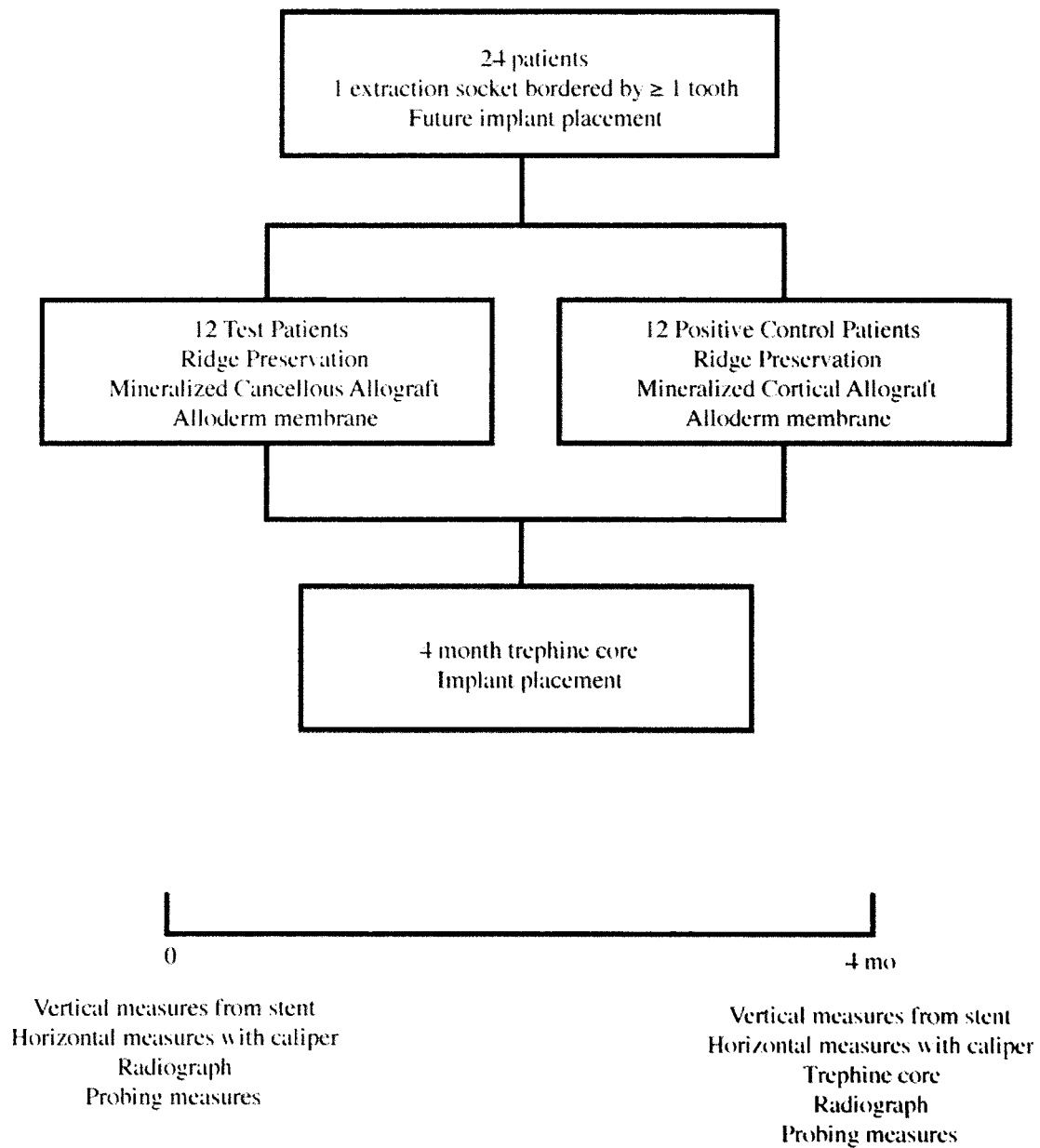
	<b>n</b>	<b>Initial</b>	<b>Final</b>	<b>Change</b>	<b>% Change</b>
<b>Maxillary Incisor</b>	33	7.8 ± 1.0	6.0 ± 1.3	-1.8 ± 1.2	-22 ± 14
<b>Mandibular Incisor</b>	2	5.9 ± 0.2	5.1 ± 0.0	-0.9 ± 0.2	-15 ± 3
<b>Maxillary Canine</b>	4	8.7 ± 0.8	6.6 ± 2.2	-2.1 ± 1.6	-25 ± 20
<b>Mandibular Canine</b>	3	7.8 ± 1.8	7.0 ± 2.5	-0.8 ± 1.7	-9 ± 23
<b>Maxillary Premolar</b>	78	9.4 ± 1.2	8.2 ± 1.4	-1.2 ± 1.1	-13 ± 11
<b>Mandibular Premolar</b>	17	7.9 ± 1.3	7.5 ± 1.3	-0.4 ± 0.9	-5 ± 12

## CHAPTER II

### METHODS

**Study design.** A total of 24 patients requiring extraction of a nonmolar tooth to be replaced by a dental implant participated in this 4-month randomized, controlled, single blinded clinical trial. Twelve positive control patients were randomly selected, using a coin toss, to receive a cortical particulate 500-800  $\mu\text{m}$  allograft plus an acellular dermal matrix (ADM) barrier membrane (Alloderm®, Lifecell Corp. Somerville, NJ), while twelve test patients were selected to receive a cancellous particulate 500-800  $\mu\text{m}$  allograft plus an ADM barrier. Both groups received a full thickness papilla preservation flap on the buccal and lingual/palatal. All surgical procedures were completed by one operator (MS) under the direction of one mentor (HG). The surgeon was trained in the procedures until considered proficient. All measurements were performed by a blinded examiner (AE). The mentor performed the coin toss and verified the measurements taken by the blinded examiner. All patients signed an informed consent approved by the University of Louisville Institutional Review Board in July 2009. The study was conducted between August 7, 2009 and April 9, 2010 in the Graduate Periodontics clinic. At 4-months post-surgery, a trephine was used to obtain an osseous core from the grafted site prior to the osteotomy for implant placement. Trephine cores were sectioned and prepared for histologic analysis using hematoxylin and eosin staining.

**Figure 1**



**Inclusion Criteria.** Patients were included in the study if they: 1) had at least one non-molar tooth requiring extraction that will be replaced by a dental implant; 2) had at least one site bordered by at least one tooth; 3) were at least 18 years old; and 4) signed an informed consent approved by the University of Louisville Human Studies Committee.

**Exclusion Criteria.** Patients were excluded if any of the following were present:

1) debilitating systemic diseases, or diseases that affect the periodontium; 2) molar teeth; 3) the patient had an allergy to any material or medication used in the study; 4) the patient required prophylactic antibiotics; 5) the patient had previous head and neck radiation therapy; 6) the patient received chemotherapy in the previous 12 months; or 7) if the patient was on long term NSAID or steroid therapy.

**Post-Surgical Exclusion.** Any site excluded after surgery was reported. Sites were excluded if there was: 1) loss of graft or barrier material; or 2) unanticipated healing complications that adversely affected treatment results.

**Presurgical Management.** Each patient received a diagnostic work-up including standardized periapical radiographs (Appendix D), study casts, clinical photographs, and a clinical examination to record attachment level, probing depth, recession, and mobility of teeth adjacent to the extracted sites. Customized Triad® occlusal stents were fabricated on the study casts to serve as fixed reference guides for the measurements (Appendix F).

Presurgical preparation included detailed oral hygiene instructions. Baseline data was collected just before the surgical phase of the treatment. Baseline data included: 1) Plaque index (Silness and Løe 1964, Appendix A); 2) Gingival index (Loe 1967, Appendix B); 3) Bleeding on Probing Index (Tagge 1975, Appendix C); 4) Gingival margin levels measured from CEJ to the gingival margin; 5) Keratinized tissue measured from the gingival margin to the mucogingival junction; 6) Clinical attachment level measured from CEJ to the bottom of the clinical periodontal pocket; 7) Clinical tooth mobility measured by using the modified Miller's Index; 8) Horizontal ridge width



measured using a digital caliper to the nearest  $10^{-2}$  mm at the mid point of the alveolar crest and 5 mm apical to the crest, measured post-extraction and prior to implant placement; 9) Vertical change in the alveolar crest measured post-extraction from the stent to alveolar crest minus re-entry stent to alveolar crest values; 10) Radiographic examination using a customized stent constructed using Triad® light cured resin (Appendix F) and a Rinn-XCP on the patient model (Appendix D) to ensure standardization of the projection; and 11) Clinical photographs.

**Surgical Treatment.** Patients were anesthetized with 2% lidocaine containing epinephrine in both 1:100,000 and 1:50,000 concentrations. Full-thickness mucoperiosteal flaps were elevated on the buccal and palatal/ lingual using a papilla preservation technique. An acrylic stent was used to obtain vertical ridge height measurements relative to the stent.

A digital caliper was utilized to obtain horizontal ridge dimension at the mid-socket crest and 5 mm apical to the crest. The positive control patients received a cortical particulate 500-800  $\mu\text{m}$  graft and the test patients received an allograft composed of cancellous particulate 500-800  $\mu\text{m}$ . Both groups were covered using an acellular dermal matrix barrier membrane (Alloderm®, Lifecell Corp. Somerville, NJ). The flaps were replaced and sutured with 4-0 Cytoplast PTFE sutures (Osteogenics Biomedical Lubbock, TX). Subjects were given a post-surgical regimen of naproxen sodium (Geneva Pharmaceuticals, Inc. Broomfield, CO), 375 mg, every 12 hours for 1 week; doxycycline hyclate 50 mg once daily (Warner Chilcott Inc. Morris Plains, New Jersey) for 2 weeks, and narcotic analgesics as needed. Postoperative care was given at 2, 4, 8, and 12 weeks. Photographs were taken at each postoperative appointment.

**Re-entry Surgery.** At 4 months, a standardized radiograph was taken and all baseline measurements were repeated. Patients were anesthetized with 2% lidocaine containing epinephrine in both 1:100,000 and 1:50,000 concentrations. Full-thickness mucoperiosteal flaps were elevated on the buccal and palatal/lingual using a papilla preservation technique. An acrylic stent was used to obtain vertical ridge height measurements relative to the stent. A digital caliper was utilized to obtain horizontal ridge dimension at the mid-buccal crest and 5 mm apical to the crest.

At 4 months post-surgery, a 2.7 x 6.0 mm trephine (H & H Company Ontario, California) was used to remove a core from the grafted site prior to osteotomy for implant placement. The core was placed into 10% buffered formalin for histologic preservation. An osteotomy site was prepared and an endosseous dental implant was placed. The flaps were replaced and sutured with 4-0 silk sutures. Patients were again given naproxen 375 mg, doxycycline hyclate 50 mg and analgesics as needed.

**Histology.** Trephine cores (2.7 X 6 mm) were decalcified and step serial sections were taken from each longitudinally sectioned core. The sections were stained with hematoxylin and eosin. Ten slides per patient were prepared with at least 4 sections per slide. For each patient 6 of 10 slides were assessed. The mean percentage of vital and non-vital bone and trabecular space was calculated for each patient by using an American Optical microscope at 150X with a 10 X 10 ocular grid.

**Statistical Analysis.** Means and standard deviations were calculated for all parameters. A paired t-test was used to evaluate the statistical significance of the differences between initial and final data. An unpaired t-test was used to evaluate statistical differences between the test and control groups. The sample size of 12 per

group gave 83% statistical power to detect a difference of 1 mm between groups. Power calculations were based on data from previous studies.

## CHAPTER III

### RESULTS

A total of 9 females and 3 males with a mean age of  $58 \pm 14$ , ranging from 34 to 83, were enrolled in the Cancellous group while 8 females and 4 males with a mean age of  $60 \pm 10$ , ranging from 34 to 71, were enrolled in the Cortical group. The Cancellous group consisted of 4 maxillary incisors, 5 maxillary premolars, 1 mandibular canine and 2 mandibular premolars. The Cortical group consisted of 6 maxillary incisors, 4 maxillary premolars, 1 mandibular incisor and 1 mandibular canine. There were no smokers enrolled in either group. Data from this study were derived from 24 patients all treated by one operator (MS). There was one post-surgical exclusion due to loss of graft material observed at the 2-week post-op visit.

**Clinical Indices.** Plaque index, gingival index and bleeding on probing had low initial values for both groups and the majority of values only changed slightly by the 4 month reentry (Table 16). The plaque index for the Cortical group decreased significantly from initial to final values ( $p < 0.05$ , Table 16).

**Horizontal Ridge Width Changes.** The Cancellous group presented with a mean crestal width of  $8.4 \pm 1.1$  mm, which decreased to  $6.3 \pm 1.6$  mm at the 4 month reentry for a mean loss of  $2.0 \pm 1.6$  mm ( $p < 0.05$ , Table 17). For the Cortical group the mean initial width at the crest was  $8.6 \pm 2.0$  mm, which decreased to  $6.7 \pm 2.3$  mm for a mean loss of  $1.9 \pm 1.4$  mm ( $p < 0.05$ ). The Cancellous group had a mean initial width 5

mm apical to the crest of  $9.1 \pm 0.9$  mm, which decreased to  $8.2 \pm 1.1$  mm at month 4 for a mean loss of  $1.0 \pm 0.7$  mm ( $p < 0.05$ ). The Cortical group had a mean initial width 5 mm apical to the crest of  $8.7 \pm 1.9$  mm, which decreased to  $7.8 \pm 1.9$  mm for a mean loss of  $0.9 \pm 1.3$  mm ( $p < 0.05$ ). There were no statistically significant differences between groups ( $p > 0.05$ ).

**Vertical mid-Buccal Ridge Height Changes.** The Cancellous group had a mean mid-buccal ridge height gain of  $1.3 \pm 3.3$  mm ( $p > 0.05$ , Table 18), while the Cortical group gained  $2.5 \pm 3.2$  mm ( $p < 0.05$ ). There were no statistically significance differences between the Cancellous and Cortical groups for the mid-buccal change ( $p > 0.05$ ).

**Vertical mid-Lingual Ridge Height Changes.** Mid-lingual ridge height in the Cancellous group had a mean gain of  $0.4 \pm 1.3$  mm ( $p < 0.05$ , Table 18), while the Cortical group had a mean gain of  $0.3 \pm 1.3$  mm ( $p < 0.05$ ). There were no statistically significance differences between groups ( $p > 0.05$ ).

**Vertical Mesial Ridge Height Changes.** Vertical mesial ridge height for the Cancellous group had a mean loss of  $0.2 \pm 1.1$  mm ( $p < 0.05$ , Table 18), while the Cortical group had a mean loss of  $0.1 \pm 0.7$  mm ( $p < 0.05$ ). There were no statistically significance differences between groups ( $p > 0.05$ ).

**Vertical Distal Ridge Height Changes.** Vertical distal ridge height for the Cancellous group showed a mean loss of  $0.4 \pm 1.2$  mm ( $p > 0.05$ , Table 18), while the Cortical group had no change,  $0.0 \pm 0.6$  mm ( $p > 0.05$ ). There were no statistically significance differences between groups ( $p > 0.05$ ).

**CEJ to Osseous Crest Changes.** The mesial and distal CEJ to osseous crest change for both the Cancellous and Cortical groups was minimal from time 0 to 4 ( $p > 0.05$ , Table 19). There were no statistically significant differences between groups for either mesial or distal sites ( $p > 0.05$ ).

**Histologic evaluation.** Cancellous sites healed with  $37 \pm 13\%$  vital bone,  $21 \pm 13\%$  non-vital bone,  $43 \pm 6\%$  trabecular space, while cortical sites healed with  $19 \pm 10\%$  vital bone,  $38 \pm 11\%$  non-vital bone, and  $43 \pm 11\%$  trabecular space. For vital and nonvital bone there were statistically significant differences between the Cancellous and Cortical groups ( $p < 0.05$ ), however, there were no statistically significant differences between groups for trabecular space ( $p > 0.05$ , Table 20). Histologic results from previous U of L ridge preservation studies (Table 21) and ridge augmentation studies (Table 22) are summarized to allow comparison of different grafting materials.

**Table 16**  
**Clinical Indices for Cancellous and Cortical Sites**  
**Mean ± sd in index units**

		<b>Initial</b>	<b>Final</b>	<b>Change</b>
<b>Plaque Index</b>	Cancellous	0.2 ± 0.2	0.3 ± 0.3	-0.1 ± 0.3
	Cortical	0.3 ± 0.2	0.1 ± 0.1	0.2 ± 0.2*
<b>Gingival Index</b>	Cancellous	0.6 ± 0.4	0.4 ± 0.3	0.2 ± 0.3
	Cortical	0.5 ± 0.2	0.5 ± 0.4	0.1 ± 0.5
<b>Bleeding on Probing</b>	Cancellous	0.4 ± 0.4	0.2 ± 0.2	0.1 ± 0.3
	Cortical	0.4 ± 0.3	0.3 ± 0.3	0.1 ± 0.3

\* = p < 0.05 between initial and 4-month values

**Table 17**

**Horizontal Ridge Width for Cancellous and Cortical Sites**

**Mean  $\pm$  sd in mm**

	<b>Initial</b>	<b>Final</b>	<b>Change</b>	<b>Range</b>
	<b>Initial</b>	<b>Final</b>	<b>Change</b>	<b>Range</b>
<b>Cancellous at Crest</b>	8.4 $\pm$ 1.1	6.3 $\pm$ 1.6	-2.0 $\pm$ 1.6*	-4.7 to 0.2
<b>Cortical at Crest</b>	8.6 $\pm$ 2.0	6.7 $\pm$ 2.3	-1.9 $\pm$ 1.4*	-5 to 0.6
<b>Cancellous at 5 mm</b>	9.1 $\pm$ 0.9	8.2 $\pm$ 1.1	-1.0 $\pm$ 0.7*	-2.4 to 0.7
<b>Cortical at 5 mm</b>	8.7 $\pm$ 1.9	7.8 $\pm$ 1.9	-0.9 $\pm$ 1.3*	-3.8 to 1.0

\* = p < 0.05 between initial and 4-month values



**Table 18**  
**Vertical Ridge Height Change for Cancellous and Cortical Sites**  
**Mean ± sd in mm**

Location	Cancellous	Cortical	Cancellous	Cortical
	Mean Change ± sd in mm		Range in mm	
<b>Mid-Buccal</b>	1.3 ± 3.3	2.5 ± 3.2*	-3.5 to 8.0	-1.0 to 8.5
<b>Mid-Lingual</b>	0.4 ± 1.3	0.3 ± 1.3	-2.0 to 2.5	-1.5 to 2.5
<b>Mesial</b>	-0.2 ± 1.1	-0.1 ± 0.7	-2.5 to 1.2	-0.8 to 1.5
<b>Distal</b>	-0.4 ± 1.2	0.0 ± 0.6	-3.2 to 1.5	-0.7 to -0.1

\* = p < 0.05 between initial and 4-month values

**Table 19**

**CEJ to Osseous Crest Change at Adjacent Teeth**

**Mean  $\pm$  sd in mm**

	<b>n</b>	<b>Initial</b>	<b>Final</b>	<b>Change</b>
<b><u>Cancellous</u></b>				
<b>Mesial</b>	11	3.4 $\pm$ 0.9	3.2 $\pm$ 0.8	0.2 $\pm$ 1.0
<b>Distal</b>	11	3.6 $\pm$ 1.0	3.7 $\pm$ 0.8	-0.1 $\pm$ 1.2
<b><u>Cortical</u></b>				
<b>Mesial</b>	12	3.3 $\pm$ 0.8	3.3 $\pm$ 0.9	0.0 $\pm$ 0.6
<b>Distal</b>	11	3.7 $\pm$ 0.9	3.1 $\pm$ 0.9	0.5 $\pm$ 1.3

**Table 20**

**Histologic Data at Implacment for Cancellous and Cortical Sites**

**Mean  $\pm$  sd**

<b>Group</b>	<b>Time</b>	<b>n</b>	<b>% Vital</b>	<b>% Non-vital</b>	<b>% Trabecular</b>
<b>Cancellous</b>	4 month	12	37 $\pm$ 13+	21 $\pm$ 13+	43 $\pm$ 6
<b>Cortical</b>	4 month	12	19 $\pm$ 10	38 $\pm$ 11	43 $\pm$ 11

+ =  $p < 0.05$  between cortical and cancellous groups

**Table 21**  
**Comparison of Histologic Data from U of L Ridge Preservation Studies**

**Mean ± sd**

<b>Study</b>	<b>Treatment</b>	<b>Time in mo</b>	<b>n</b>	<b>% Vital</b>	<b>% Non-vital</b>	<b>% Trabecular</b>
<b>Iasella et al. 2003</b>	FDBA/BioMend	4 - 6	12	28 ± 14	37 ± 18	35 ± 10
	Extraction Alone	4 - 6	10	54 ± 12	*	44 ± 12
<b>Vance et al 2004</b>	Calmatrix	4 mo	12	61 ± 9	3 ± 3	36 ± 8
	BioOss	4 mo	12	26 ± 20	16 ± 7	59 ± 16
<b>Adams et al 2005</b>	Intra Cort/ADM	4 mo	13	37 ± 15	31 ± 15	32 ± 5
	Overlay	4 mo	13	36 ± 18	26 ± 17	38 ± 10
<b>Siu et al 2007</b>	Flap GMP/MnOs	4 mo	12	35 ± 15	19 ± 12	46 ± 17
	Flapless	4 mo	12	44 ± 10	17 ± 13	39 ± 9
<b>Witonsky et al 2009</b>	CancBioOss/CP	4 mo	12	28 ± 20	37 ± 16	35 ± 13
	Cort/PTFE	4 mo	12	35 ± 21	31 ± 22	34 ± 10
<b>Sams et al 2010</b>	Cancellous	4 mo	12	37 ± 13+	21 ± 13+	43 ± 6
	Cortical	4 mo	12	19 ± 10	38 ± 11	43 ± 11

**Table 22**  
**Comparison of Histologic Data from U of L Ridge Augmentation Studies**

**Mean ± sd**

<b>Study</b>	<b>Treatment</b>	<b>Time in mo</b>	<b>n</b>	<b>% Vital</b>	<b>% Non-vital</b>	<b>% Trabecular</b>
<b>Cordini et al. 2005</b>	Canc Block	4	8	33 ± 25	24 ± 18	42 ± 12
	ADM membrane					
	DBM (Graf Flex)	4	2	56 ± 9	5 ± 5	38 ± 3
<b>Lahey et al. 2005</b>	Canc Block	4	11	51 ± 18	11 ± 9	39 ± 14
	ADM membrane					
	Particulate Cort	4	10	58 ± 12	11 ± 7	31 ± 7
<b>Claggett et al. 2006</b>	Canc Block	4	11	56 ± 12	8 ± 6	36 ± 10
	ADM membrane					
	Paste (Regen)	4	10	53 ± 10	8 ± 8	36 ± 13
<b>Dib et al. 2007</b>	Canc Block	4	11	57 ± 10	11 ± 10	32 ± 10
	ADM membrane					
	GMP/MnOss	4	12	60 ± 13	7 ± 9	33 ± 11
<b>Ratliff et al. 2009</b>	Cortical	4	11	47 ± 11	4 ± 4	49 ± 9
	ADM membrane					
	Cancellous	4	11	58 ± 11+	5 ± 6	37 ± 8

## CHAPTER IV

### DISCUSSION

In this 4-month randomized, controlled, blinded clinical study of intrasocket ridge preservation in humans two different mineralized particulate allografts were compared. One group received a cancellous allograft (Cancellous group) while the other received a cortical allograft (Cortical group). An acellular dermal matrix barrier membrane was used for both groups. In terms of clinical ridge dimensions there were no significant differences between groups ( $p > 0.05$ ). Histologic evaluation of trephine cores revealed a significantly greater percentage of vital bone and significantly smaller percentage of nonvital bone (residual graft particles) in the Cancellous group ( $p < 0.05$ ).

The clinical ridge dimension results in this study are within the range reported in previous studies, which varies from -3.5 to + 1.1 mm (Table 8). The mean horizontal loss reported from those studies was  $2.0 \pm 1.1$  mm. In this study the cortical group lost  $1.9 \pm 1.4$  mm while the cancellous group lost  $2.0 \pm 1.6$  mm.

Previous reports of extraction alone showed a mean horizontal loss of  $3.7 \pm 1.7$  mm or  $43 \pm 17\%$  of the initial ridge width (Table 6). In contrast, previous ridge preservation studies show a mean percent horizontal loss of  $12 \pm 16\%$  (Table 9). Thus use of a ridge preservation procedure appears to be beneficial in terms of preserving ridge width.

Mean ridge height change showed a mean gain on the mid-buccal of 1.3 and 2.5 mm for the Cancellous and Cortical groups respectively, which was not significantly different between groups ( $p > 0.05$ ). Previous ridge preservation studies showed a mean ridge height loss of  $-0.1 \pm 0.8$  mm (Table 8), while extraction alone studies showed a mean loss of  $-1.2 \pm 1.1$  mm. Thus the primary change that occurs following extraction alone is loss of horizontal width while the vertical height change is minimally affected.

Previous animal studies have shown that following tooth extraction the primary change that takes place during socket healing is loss of bundle bone (Araujo & Lindhe 2005). This is most significant in the coronal third of the buccal plate, where the entire thickness of the plate may be composed of bundle bone (Araujo & Lindhe 2009). This clearly explains why loss of ridge width during healing is the primary problem following extraction alone. Even following a ridge preservation procedure there is still some loss of ridge width, which is most likely explained by loss of buccal plate in the coronal third of the socket wall. This would explain the loss that occurred in this study.

The percent vital bone was  $37 \pm 13\%$  vs.  $19 \pm 10\%$  for the Cancellous and Cortical groups respectively while the percent nonvital bone was  $21 \pm 13\%$  vs.  $38 \pm 11\%$  for the Cancellous and Cortical groups respectively. Both of these differences were significant between groups ( $p < 0.05$ ). Cancellous autografts revascularize earlier than cortical autografts and undergo a process known as creeping substitution (Burchardt 1983, Goldberg & Stevenson 1993). This means that there is an osteoblastic phase that produces appositional bone growth followed by a resorptive phase. In contrast, cortical autografts first undergo osteoclastic resorption through a process known as reverse creeping substitution, where a mixture of vital and nonvital bone may remain for an

extended period. Thus cancellous autografts tend to be almost completely replaced by native bone while cortical autografts may not resorb for an extended or indefinite period. In the histologic sections evaluated in this study the cortical grafts tended to heal with more soft tissue encapsulation while the cancellous grafts were more often surrounded by vital bone. Thus the significant advantage reported for cancellous autograft healing was also true for the cancellous allograft healing seen in this study.



## **CHAPTER V**

### **CONCLUSIONS**

Within the limits of this study design and sample size it may be concluded that:

- 1) Mean crestal ridge width was preserved for both the Cancellous and Cortical groups and there were no statistically significant differences between groups ( $p > 0.05$ ).
- 2) There was a gain of mean mid-buccal ridge height for both groups with no statistically significant differences between groups ( $p > 0.05$ ).
- 3) Histomorphometric analysis revealed that there was significantly more vital bone and significantly less nonvital bone for the Cancellous group than for the Cortical group ( $p < 0.05$ ).
- 4) Bone levels on the adjacent teeth were minimally affected as shown by the slight change in mean CEJ to osseous crest distance for both groups and there were no statistically significant differences between groups ( $p > 0.05$ ).

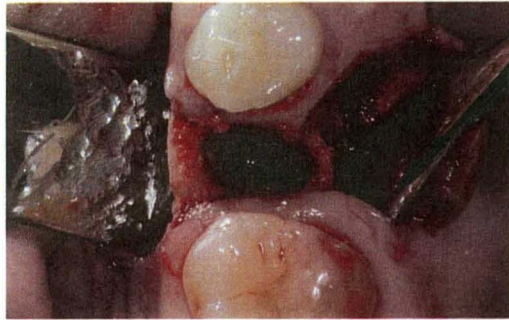
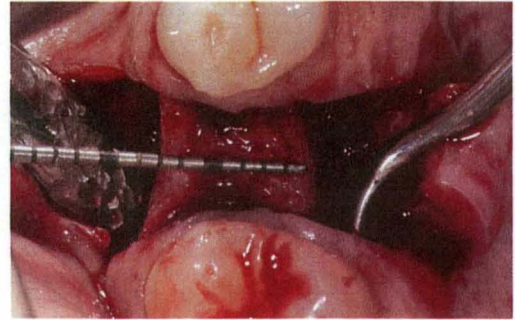


Figure 2. a) Case 1, Pre-op



b) 4-month re-entry

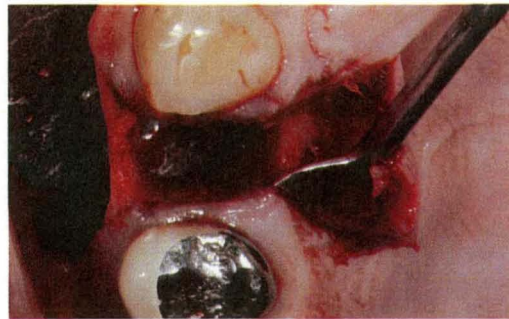
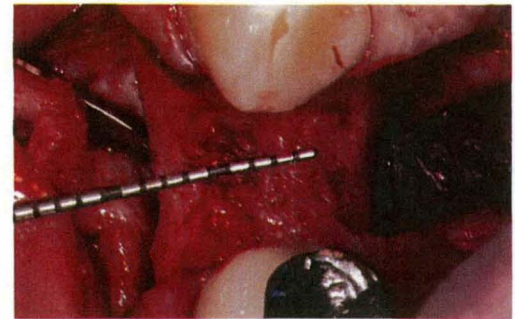


Figure 3. a) Case 2, Pre-op



b) 4-month re-entry.

### **Cancellous Allograft Group**

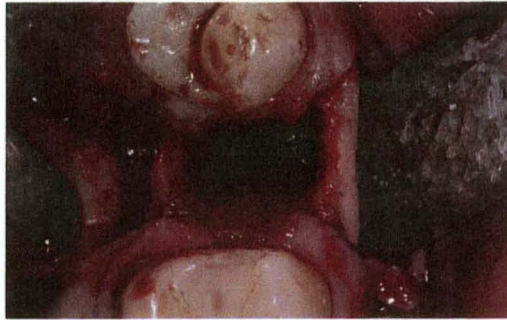
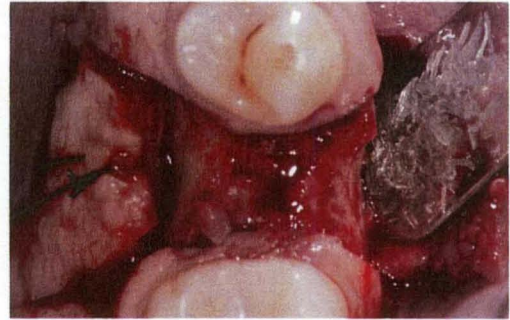


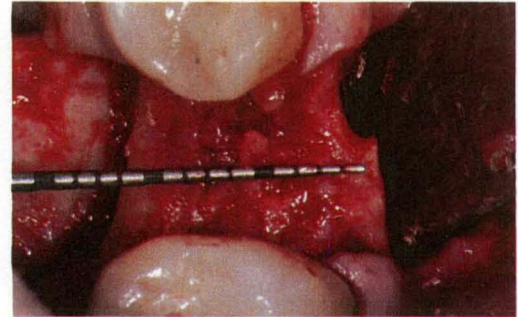
Figure 4. a) Case 3 Pre-op



b) 4-month re-entry

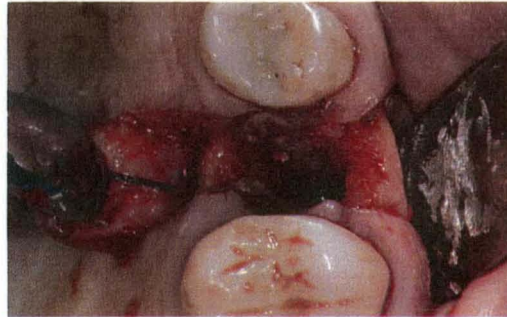

Figure 5. a) Case 4 Pre-op



b) 4-month re-entry

### Cortical Allograft Group

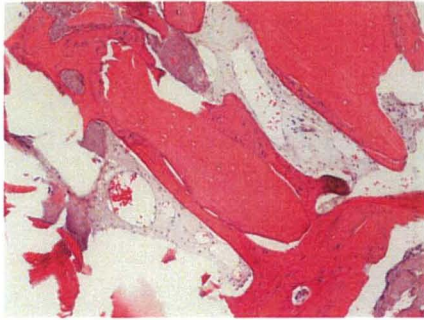
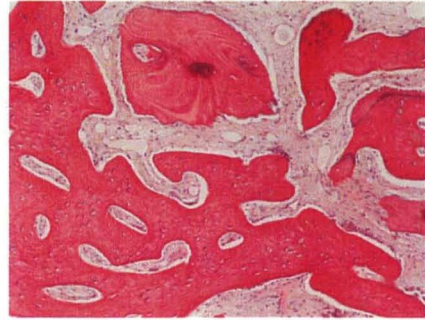

Figure 6. a) Cancellous appositional growth



b) Cancellous vital bone

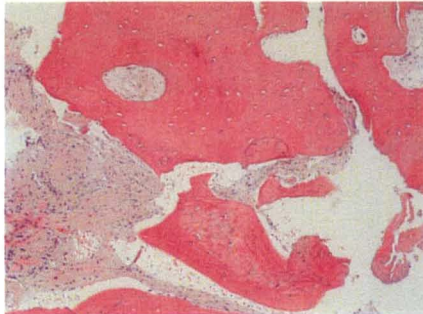
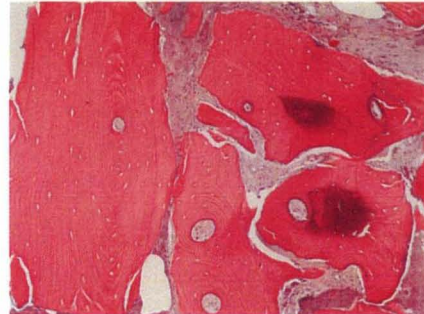


Figure 7. a) Cortical vital & nonvital



b) Cortical nonvital & fibrous

### Representative Histologic Sections

## REFERENCES

Adams DA. Ridge preservation comparing an intrasocket FDBA allograft alone to a combined intra-and extra-socket FDBA allograft both covered with acellular dermal matrix membrane. [Thesis]. Louisville, Kentucky. University of Louisville. 2005.

Amler MH, Johnson PL, Salaman I. Histologic and histochemical investigation of human alveolar socket healing in undisturbed extraction wounds. *J Am Dent Assoc* 1960;6:132-144.

Araújo M, Linder E, Wennström J, Lindhe J. The influence of Bio-Oss Collagen on healing of an extraction socket: an experimental study in the dog. *Int J Periodontics Restorative Dent* 2008;28 (2):123-135.

Araujo MG, Lindhe J. Dimensional ridge alterations following tooth extraction. An experimental study in the dog. *J Clin Periodontol* 2005;32(2):212-218.

Araújo MG, Lindhe J. Ridge alterations following tooth extraction with and without flap elevation: an experimental study in the dog. *Clin Oral Implants Res* 2009;20(6):545-549.

Artzi Z, Nemcovsky CE. The application of deproteinized bovine bone mineral for ridge preservation prior to implantation. Clinical and histological observations in a case report. *J Periodontol* 1998;69(9):1062-1067.

Artzi Z, Tal H, Dayan D. Porous bovine bone mineral in healing of human extraction sockets: Part 1: histomorphometric evaluations at 9 months. *J Periodontol* 2000;71(6):1015-1023.

Artzi Z, Tal H, Dayan D. Porous bovine bone mineral in healing of human extraction sockets: 2. Histochemical observations at 9 months. *J Periodontol* 2001;72(2):152-159.

Ash MM. *Wheeler's dental anatomy, physiology, and occlusion* (6th edition), WB Saunders Co., Philadelphia. Book 1984.

Ashman A. Postextraction ridge preservation using a synthetic alloplast. *Implant Dent* 2000;9(2):168-176.

Barone A, Aldini NN, Fini M, Giardino R, Guirado JL, Covani U. Xenograft versus extraction alone for ridge preservation after tooth removal: A clinical and histomorphometric study. *J Periodontol* 2008;79:1370-1377.

Becker W, Becker BE, Caffesse R. A comparison of demineralized freeze-dried bone and autologous bone to induce bone formation in human extraction sockets. *J Periodontol* 1994;65(12):1128-1133.

Becker W, Clokie C, Sennerby L, Urist MR, Becker BE. Histologic findings after implantation and evaluation of different grafting materials and titanium micro screws into extraction sockets. Case reports. *J Periodontol* 1998;69(4):414-421.

Becker W, Urist M, Becker BE, Jackson W, Parry DA, Bartold M, Vincenzi G, De Georges D, Niederwanger M. Clinical and histologic observations of sites implanted with intraoral autologous bone grafts or allografts. 15 human case reports. *J Periodontol* 1996;67(10):1025-1033.

Berglundh T, Lindhe J, Jonsson K, Ericsson I. The topography of the vascular systems in the periodontal and peri-implant tissues in the dog. *J Clin Periodontol* 1994;21(3):189-193.

Botticelli D, Berglundh T, Lindhe J. Resolution of bone defects of varying dimension and configuration in the marginal portion of the peri-implant bone. An experimental study in the dog. *J Clin Periodontol* 2004;31(4):309-317.

Botticelli D, Berglundh T, Persson LG, Lindhe J. Bone regeneration at implants with turned or rough surfaces in self-contained defects. An experimental study in the dog. *J Clin Periodontol* 2005;32(5):448-455.

Boyne PJ. Osseous repair of the postextraction alveolus in man. *Oral Surg Oral Med Oral Pathol* 1966;21(6):805-813.

Brkovic BM, Prasad HS, Konandreas G, Milan R, Antunovic D, Sandor GK, Rohrer MD. Simple preservation of a maxillary extraction socket using beta-tricalcium phosphate with type I: Preliminary clinical and histomorphometric observations. *J Can Dent Assoc* 2008;74(6):523-528.

Brugnam F, Then PR, Moroi H, Kabani S, Leone CW. GBR in human extraction sockets and ridge defects prior to implant placement: Clinical results and histologic evidence of osteoblastic and osteoclastic activities in DFDBA. *Int J Periodontics Restorative Dent* 1999;19(3):259-268.

Brugnam F, Then PR, Moroi H, Leone CW. Histologic evaluation of human extraction sockets treated with demineralized freeze-dried bone allograft (DFDBA) and cell occlusive membrane. *J Periodontol* 1996;67(7):821-825.

- Burchardt H. The biology of bone graft repair. *Clin Orthop Relat Res* 1983;174:28-42.
- Camargo PM, Lekovic V, Weinlaender M, Klokkevold PR, Kenney EB, Dimitrijevic B, Nedic M, Jancovic S, Orsini M. Influence of bioactive glass on changes in alveolar process dimensions after exodontia. *Oral Surg Oral Med Oral Pathol Oral Radiol Endod* 2000;90(5):581-586.
- Cardaropoli D, Cardaropoli G. Preservation of the postextraction alveolar ridge: A clinical and histologic study. *J Periodont Res* 2008;28:469-477.
- Cardaropoli G, Araujo M, Lindhe J. Dynamics of bone tissue formation in tooth extraction sites. An experimental study in dogs. *J Clin Periodontol* 2003;30(9):809-818.
- Cardaropoli G, Araujo MG, Hayacibara R, Sukekava F, Lindhe J. Healing of extraction sockets and surgically produced - augmented and non-augmented - defects in the alveolar ridge. An experimental study in the dog. *J Clin Periodontol* 2005;32(5):435-440.
- Carmagnola D, Berglundh T, Araujo M, Albrektsson T, Lindhe J. Bone healing around implants placed in a jaw defect augmented with Bio-Oss. An experimental study in dogs. *J Clin Periodontol* 2000;27(11):799-805.
- Clafin R. Healing of disturbed and undisturbed extraction sites. *J Am Dent Assoc* 1936;23(6):945-959.
- Crespi R, Capparè P, Gherlone E. Magnesium-enriched hydroxyapatite compared to calcium sulfate in the healing of human extraction sockets: radiographic and histomorphometric evaluation at 3 months. *J Periodontol* 2009;80(2):210-218.
- Evian C, Rosenberg E, Coslet J, Corn H. The osteogenic activity of bone removed from healing extraction sockets in humans. *J Periodontol* 1982;53(2):81-85.
- Fotek PD, Neiva RF, Wang HL. Comparison of dermal matrix and polytetrafluoroethylene membrane for socket bone augmentation: a clinical and histologic study. *J Periodontol* 2009;80(5):776-785.
- Froum S, Cho S, Rosenberg E, Rohrer M, Tarnow D. Histologic comparison of healing extraction sockets implanted with bioactive glass or demineralized freeze-dried bone allograft: A pilot study. *J Periodontol* 2002;73(1):94-102.
- Froum S, Cho SC, Elian N, Rosenberg E, Rohrer M, Tarnow D. Extraction sockets and implantation of hydroxyapatites with membrane barriers a histologic study. *Implant Dent* 2004;13(2):153-161.
- Garg AK. Alveolar ridge preservation during and after surgical tooth removal. *Dent Implantol Update* 2001;11(8):57-62.

Goldberg VM, Stevenson S. The biology of bone grafts. *Semin Arthroplasty* 1993;4(2):58-63.

Guarnieri R, Pecora G, Fini M, Nicoli Aldini N, Giardino R, Orsini G, Piattelli A. Medical grade calcium sulfate hemihydrate in healing of human extraction sockets: Clinical and histological observations at 3 months. *J Periodontol* 2004;75(5):902-908.

Horowitz RA. Extraction environment enhancement: Critical evaluation of early socket healing in long-term barrier protected extraction sockets. *Compend Contin Educ Dent* 2005;26(10):703-713.

Iasella JM, Greenwell H, Miller RL, Hill M, Drisko C, Bohra AA, Scheetz JP. Ridge preservation with freeze dried bone allograft and a collagen membrane compared to extraction alone for implant site development: A clinical and histologic study in humans. *J Periodontol* 2003;74(7):988-997.

Lekholm U, Zarb GA. Patient selection and preparation. In Branemark P-I, Zarb GA, Albrektsson T, editors: *Tissue integrated prostheses: osseointegration in clinical dentistry*. Chicago: Qunitessence. Book 1985;199-209.

Lekovic V, Camargo PM, Klokkevold PR, Weinlaender M, Kenney EB, Dimitrijevic B, Nedic M. Preservation of alveolar bone in extraction sockets using bioabsorbable membranes. *J Periodontol*. 1998;69(9):1044-1049.

Lekovic V, Kenney EB, Weinlaender M, Han T, Klokkevold P, Nedic M, Orsini M. A bone regenerative approach to alveolar ridge maintenance following tooth extraction. Report of 10 cases. *J Periodontol* 1997;68(6):563-570.

Loe H. The gingival index, the plaque index and the retention index systems. *J Periodontol* 1967;38(Suppl):610-617.

Luczyszyn SM, Papalexiou V, Novaes AB Jr, Grisi MF, Souza SL, Taba M Jr. Acellular dermal matrix and hydroxyapatite in prevention of ridge deformities after tooth extraction. *Implant Dent* 2005;14(2):176-184.

MacNeill SR, Cobb CM, Rapley JW, Glaros AG, Spencer P. In vivo comparison of synthetic osseous graft materials. A preliminary study. *J Clin Periodontol* 1999;26(4):239-245.

Mangano C, Piattelli A, Perrotti V, Iezzi G. Dense hydroxyapatite inserted into postextraction sockets: A histologic and histomorphometric 20-year case report. *J Periodontol* 2008;79:929-933.

Mellonig J. Freeze-Dried bone allografts in periodontal reconstructive surgery. *Dent Clin North Am* 1991;35(3):505-520.



Mellonig J, Bowers G, Cotton W. Comparison of bone graft materials. Part II. New bone formation with autografts and allografts: A histological evaluation. *J Periodontol* 1981;52(6):297-302.

Neiva RF, Tsao YP, Eber R, Shotwell J, Billy E, Wang HL. Effects of a putty-form hydroxyapatite matrix combined with the synthetic cell-binding peptide p-15 on alveolar ridge preservation. *J Periodontol* 2008;79:291-299.

Nemcovsky CE, Artzi Z. Split palatal flap. I. A surgical approach for primary soft tissue healing in ridge augmentation procedures: Technique and clinical results. *Int J Periodontics Restorative Dent* 1999;19(2):175-182.

Nemcovsky CE, Serfaty V. Alveolar ridge preservation following extraction of maxillary anterior teeth. Report on 23 consecutive cases. *J Periodontol* 1996;67(4):390-395.

Nevins ML, Camelo M, Schupbach P, Kim DM, Camelo JM, Nevins M. Human histologic evaluation of mineralized collagen bone substitute and recombinant platelet-derived growth factor-BB to create bone for implant placement in extraction socket defects at 4 and 6 months: a case series. *Int J Periodontics Restorative Dent* 2009;29(2):129-139.

Pietrokovski J, Massler M. Alveolar ridge resorption following tooth extraction. *J Prosth Dent* 1967;17(1):21-27.

Schropp L, Wenzel A, Kostopoulos L, Karring T. Bone healing and soft tissue contour changes following single-tooth extraction: A clinical and radiographic 12 month prospective study. *Int J Periodontics Restorative Dent* 2003;23(4):313-323.

Schwartz Z, Mellonig JT, Carnes DL Jr, De La Fontaine J, Cochran DL, Dean DD, Boyan BD. Ability of commercial demineralized freeze-dried bone allograft to induce new bone formation. *J Periodontol* 1996;67(9):918-926.

Schwartz Z, Somers A, Mellonig JT, Carnes DL, Dean DD, Cochran DL, Boyan BD. Ability of commercial demineralized freeze-dried bone allograft to induce new bone formation is dependent on donor age but not gender. *J Periodontol* 1998;69(4):470-478.

Schwartz Z, Weesner T, van Dijk S, Cochran DL, Mellonig JT, Lohmann CH, Carnes DL, Goldstein M, Dean DD, Boyan BD. Ability of deproteinized cancellous bovine bone to induce new bone formation. *J Periodontol* 2000;71(8):1258-1269.

Serino G, Biancu S, Iezzi G, Piatelli A. Ridge preservation following tooth extraction using a polylactide and polyglycolic sponge as space filler: a clinical and histological study in humans. *Clin Oral Implants Res* 2003;14(5):651-658.

Silness J, Løe H. Periodontal disease in pregnancy. II. Correlation between oral hygiene and periodontal conditions. *Acta Odontol Scand* 1964;22(1):121-135.

Simon BI, Von Hagen S, Deasy MJ, Faldu M, Resnansky D. Changes in alveolar bone height and width following ridge augmentation using bone graft and membranes. *J Periodontol* 2000;71(1):1774-1791.

Siu TL. Ridge preservation comparing a flap vs. flapless technique using a demineralized bone matrix allograft plus mineralized particulate allograft and covered with a calcium sulfate barrier. [Thesis]. Louisville, Kentucky. University of Louisville. 2007.

Smukler H, Landi L, Setayesh R. Histomorphometric evaluation of extraction sockets and deficient alveolar ridges treated with allograft and barrier membrane: A pilot study. *Int J Oral Maxillofac Implants* 1999;14(3):407-416.

Tagge DL, O'Leary TJ, El-Kafrawy AH. The clinical and histological response of periodontal pockets to root planing and oral hygiene. *J Periodontol* 1975;46(9):527-533.

Urist MR, Strates BS. Bone morphogenetic protein. *J Dent Res* 1971;50(9):1392-1406.

Vance GS, Greenwell H, Miller RL, Hill M, Johnston H, Scheetz JP. Comparison of an allograft in an experimental putty carrier and a bovine-derived xenograft used in ridge preservation: A clinical and histologic study in humans. *Int J Oral Maxillofac Implants* 2004;19(4):491-497.

Wang HL, Sao JP. Histologic evaluation of socket augmentation with mineralized human allograft. *Int J Periodontics Restorative Dent* 2008;28(3):231-237.

Woelfel JB. *Dental Anatomy: Its Relevance to Dentistry*. Fourth Edition . Philadelphia: Lea & Febiger. Book 1990.

Yilmaz S, Efeoglu E, Kilic AR. Alveolar ridge reconstruction and/or preservation using root form bioglass cones. *J Clin Periodontol* 1998;25(10):832-839.

Zitzmann NU, Naef R, Scharer P. Resorbable versus nonresorbable membranes in combination with Bio-Oss for guided bone regeneration. *Int J Oral Maxillofac Implants* 1997;12(3):844-852.

Zitzmann NU, Scharer P, Marinello CP, Schupbach P, Berglundh T. Alveolar ridge augmentation with Bio-Oss: A histologic study in humans. *Int J Periodontics Restorative Dent* 2001;21(3):289-296.

Zubillaga G, Von Hagen S, Simon BI, Deasy MJ. Changes in alveolar bone height and width following post-extraction ridge augmentation using a fixed bioabsorbable membrane and demineralized freeze-dried bone osteoinductive graft. *J Periodontol* 2003;74(7):965-975.

## Appendix A

### The Plaque Index

The plaque index of Silness and Loe (1964) was measured. Scores were as follows:

0 - No plaque

1 - A film of plaque adhering to the free gingival margin and adjacent area of the tooth.

The plaque may be seen in situ only after application of disclosing solution or by using the probe on the tooth surface.

2 - Moderate accumulation of soft deposits within the gingival pocket, or on the tooth and gingival margin, which can be seen with the naked eye.

3 - Abundance of soft matter within the gingival pocket and/or on the tooth and gingival margin.

Each gingival unit (buccal, lingual, mesiobuccal, distobuccal, mesiolingual, and distolingual) of the individual tooth was given a score from 0-3, called the plaque index for the area. The scores from the 6 areas of the tooth were added and divided by 6 to give the plaque index for the tooth.

## **Appendix B**

### **Gingival Index**

The gingival index of Loe (1967) was measured for the extracted tooth and any adjacent teeth. Scores were be recorded as follows:

0 = Normal gingiva.

1 = Mild inflammation - slight change in color slight edema, no bleeding on probing.

2 = Moderate inflammation - redness, edema, and glazing, bleeding on probing.

3 = Severe inflammation - marked redness and edema, ulceration and tendency to spontaneous bleeding.

Each gingival unit (mesiobuccal, buccal, distobuccal, distolingual, lingual, mesiolingual) of the tooth was given a score 0-3. The scores for each unit were added together and divided by 6 to give the gingival index for that tooth. The score of the test tooth and the two adjacent teeth were added and divided by 3 to give the gingival index for the test of control sites.

## Appendix C

### Bleeding on Probing Index

Tagge et al. (1975) reported on the use of an index of bleeding upon probing to show the amount of hemorrhage within the periodontal sulcus. The following is the index used to record bleeding on probing:

0 = No bleeding

1 = Mild – a bleeding point appearing 10 to 30 seconds after withdrawing the probe.

2 = Moderate – bleeding when probing produces an almost immediate, but non-continuous bleeding.

3 = Severe – bleeding when gentle probing elicits immediate and continuous bleeding.

## **Appendix D**

### **Standardized Radiographic technique**

An occlusal stent was used to provide a stable foundation for the radiograph holder. A light cured resin material was placed on a Rinn radiograph holder and positioned to allow as near as possible paralleling technique. This material was light cured so that standardized radiographs can be compared. Radiographs were taken at baseline and 4 months.

## Appendix E

### Arithmetic determinations:

**Ridge width (Post-extraction)** = A digital caliper was used to measure total mid-socket ridge width to the nearest  $10^{-2}$  mm at the alveolar crest and 5 mm from the alveolar crest.

**Ridge width (4 month re-entry)** = Again, a digital caliper measured total ridge width to the nearest  $10^{-2}$  mm at one point, mid socket, at the alveolar crest and 5 mm from the alveolar crest.

**Change in alveolar crest height** = Initial: stent to alveolar crest minus re-entry stent to alveolar crest.

## **Appendix F**

### **Stent fabrication**

Rigid stents were made of 3 mm thick light cured resin material in order to provide reproducible measurements. The tooth to be extracted was ground off the model and the light cured resin material was pressed over a cast. Three channels were prepared on the labial and three on the palato/lingual aspect of the stent in which a North Carolina periodontal probe was placed so that mesial, mid and distal measurements could be made on the labial and palato/lingual aspects of the crestal bone. Additionally, two channels were also prepared on the occlusal portion of the stent to provide measures of mesial and distal occlusal ridge height. Holes were prepared with a high-speed hand-piece. In this way, reproducible probing spots and directions of probe insertions were possible.



## **CURRICULUM VITAE**

Marquez J. Sams, DMD, MS

### **EDUCATION**

2007-2010 University of Louisville Graduate Periodontics  
Certificate in Periodontics

2007-2010 University of Louisville  
Master of Science in Oral Biology

2006-2007 Palmetto Health Richland, General Practice Residency  
Certificate in General Practice Residency

2002-2006 University of Louisville of Dental Dentistry  
Doctor Medicine Dentistry (D.M.D)

1998-2002 Rhodes College  
Bachelor of Art (B.A.)

### **LICENSURE**

January 2010-Present Kansas Dental License

June 2006-Present Kentucky Dental License

June 2006-2008 South Carolina Dental License

Category II Laser certification 2007

DEA licensure granted 2006

ACLS certification 2008

### **PROFESSIONAL ASSOCIATIONS**

American Dental Association member

American Academy of Periodontology member

Academy of Osseointegration member

Kentucky Dental Association member

South Carolina Dental Association member

Christian Medical and Dental Association member

### **EXTERNSHIPS**

Anesthesiology Rotation, Palmetto Health Richland Hospital, September 2006

Emergency Medicine Rotation, Palmetto Health Richland Hospital, October 2006

Internal Medicine Rotation, University of Louisville Hospital, May 2007

Anesthesiology Rotation, University of Louisville Hospital, June 2006